

How to distinguish between surgical and non-surgical pneumoperitoneum?

FILIP ČEČKA • OTAKAR SOTONA • ZDENĚK ŠUBRT

FILIP ČEČKA, (✉) •

OTAKAR SOTONA

Department of Surgery, Faculty of Medicine
and University Hospital Hradec Králové
Sokolská 581, 500 05 Hradec Králové
Czech Republic

Phone: ++420-49583-4272

Fax: ++420-495-832026

E-mail: filip.cecka@seznam.cz

ZDENĚK ŠUBRT

Department of Field Surgery, Military Health
Science Faculty Hradec Králové
Defence University Brno, Czech Republic

ABSTRACT

Not all cases of pneumoperitoneum found on abdominal X-ray or computed tomography (CT) scan are caused by hollow viscus perforation. Non-surgical or spontaneous pneumoperitoneum is a repeatedly described entity. However, not all physicians in emergency departments are aware of it, and in such cases unnecessary laparotomy is often performed which reveals no intra-abdominal pathology. Non-surgical pneumoperitoneum can have thoracic, abdominal, gynecological, or other causes. When we acknowledge the possibility of non-surgical pneumoperitoneum, the primary goal is to discern surgical from non-surgical pneumoperitoneum. Identifying cases in which laparotomy can be avoided is important to prevent unnecessary surgery and its associated morbidity and financial costs. In this paper we propose a practical algorithm which may help the attending physicians to distinguish between surgical and non-surgical pneumoperitoneum.

Key words: non-surgical pneumoperitoneum, postoperative pneumoperitoneum, positive end-expiratory pressure, endoscopy, percutaneous endoscopic gastrostomy, peritoneal dialysis, postcoital pneumoperitoneum

Introduction

Patients with acute abdomen are commonly encountered in departments of emergency medicine around the world. The examination process of these patients includes a plain abdominal X-ray in the majority of cases, as it is an easy, low-cost, non-invasive and efficient method of searching for intra-abdominal pathology, mainly pneumoperitoneum. Emergency physicians are often the first to recognize pneumoperitoneum in the patient. Therefore, they should be aware of the possible causes of non-surgical pneumoperitoneum and should play the decisive role

in preventing needless laparotomy in these patients.

The term pneumoperitoneum is used to describe an abnormal collection of air within the peritoneal cavity. It is most commonly considered a radiological term. Abdominal X-ray has been included in diagnosing abdominal pathology since the early 1900's. (1) Nowadays abdominal X-ray should be included as a routine examination in investigating the acute abdomen. (2) Abdominal X-ray is an easy and efficient method in detecting free air in the abdominal cavity. The direction of the X-ray must be horizontal. If the patient is not capable of standing, positioning the patient on the left flank is sufficient in most cases. The best results are obtained if the patient stands upright 10 minutes prior to the examination.

Pneumoperitoneum is visible on abdominal X-ray in 85% of cases with a rupture of a hollow organ. In case of

suspicion for perforation and no pneumoperitoneum being visible on abdominal X-ray, a computed tomography (CT) scan should be more helpful. CT scans reveal pneumoperitoneum in up to 95% of cases with a ruptured hollow organ. CT is clearly superior to upright plain abdominal X-ray. (3) Generally, prompt surgical intervention is warranted in these cases in order to reduce enteric contamination within the peritoneal cavity with subsequent peritonitis and to prevent its consequences, e.g. intra-abdominal abscesses, sepsis with multi-organ failure, etc. with possibly lethal consequences. (4)

However, not all cases of pneumoperitoneum are caused by viscus perforation. The term "non-surgical" or "spontaneous" or "misleading" pneumoperitoneum is very well known since the first description of pneumoperitoneum on abdominal X-ray. (5) Even nowadays, not all physicians are aware of this enti-

Table 1. Causes of spontaneous pneumoperitoneum.

thoracic	PEEP ventilation
	pneumothorax/pneumomediastinum
	barotrauma/thoracic trauma
	bronchoscopy
	cardiopulmonary resuscitation with mouth-to-mouth ventilation
	adenotonsillectomy
	pulmonary tuberculosis
	severe coughing
	bronchopulmonary fistula
abdominal	postoperative - after laparoscopy / laparotomy
	endoscopic procedures
	postpolypectomy syndrome
	PEG - percutaneous endoscopic gastrostomy
	pneumatosis cystoides intestinalis
	peritoneal dialysis
gynecologic	vaginal insufflation
	vaginal douching
	coitus
	post-partum exercise
	knee-chest exercise
	gynecologic examination procedures
	pelvic inflammatory diseases
	aquatic sports, scuba diving, Jacuzzi use

other and idiopathic

PEEP, positive end-expiratory pressure; PEG, percutaneous endoscopic gastrostomy.

ty, and often unnecessary laparotomy is performed which elicits no abnormalities and no viscus perforation is found. (6)

An electronic search of Medline and Pubmed was undertaken; the terms "non-surgical pneumoperitoneum", "spontaneous pneumoperitoneum", and "misleading pneumoperitoneum" were used. Manual cross-referencing was also performed to find further relevant articles. With non-surgical pneumoperitoneum being a relatively rare entity, current knowledge of it is based only on case reports, small case-series and a few reviews. No paper has systematically addressed the question of how to distinguish between surgical and non-surgical pneumoperitoneum.

The aim of this work is to summarize causes of non-surgical pneumoperitoneum based on literature review and our own experience. Furthermore the main goal of this study is to propose a decision-making algorithm that can help to distinguish between surgical and non-surgical cases of pneumoperitoneum.

Illustrative cases

Figure 1. An 83-year-old female treated for non-resectable pancreatic head carcinoma. A duodenal stent was inserted due to duodenal stenosis. The third day after the procedure pneumoperitoneum was found incidentally. The patient was in good clinical condition. No laparotomy was performed and the patient was discharged home.

Figure 2. A 78-year-old male treated for septic shock in an intensive care unit. The aetiology was probably meningococcal meningitis. The patient had multi-organ failure and artificial ventilation with PEEP (positive end-expiratory pressure). Massive pneumoperitoneum was found incidentally on a CT scan. Clinically, the abdomen was tender. We decided not to perform a laparotomy. The condition of the patient gradually improved and the pneumoperitoneum resolved.

Figure 3. A 63-year-old male with incidentally found pneumoperitoneum on a chest X-ray taken the 4th day after bullectomy and left sided pleurectomy. Clinical condition was stable and the patient did not complain of abdominal pain, thus laparotomy was not considered and the patient was discharged home in good condition.

Definition and aetiology

Spontaneous pneumoperitoneum or non-surgical pneumoperitoneum or misleading pneumoperitoneum is defined as the finding of free air in the peritoneal cavity on radiological examinations which is not caused by viscus perforation and surgical intervention is not mandatory; and when laparotomy is performed, no perforation is found. (7,8)

It is often an incidental finding on chest X-ray, which is performed for other reasons, e.g. suspicion for pneumonia, suspicion for pneumothorax, or other intra-thoracic abnormalities.

However, even non-surgical pneumoperitoneum can be symptomatic. Patients often arrive at the emergency room with abdominal pain or other symptoms. The emergency physician must be aware of the most common causes of non-surgical pneumoperitoneum; they are mentioned in table 1.

A/ Thoracic causes

Intrathoracic causes of spontaneous pneumoperitoneum are the most frequently reported. Positive pressure ventilation may lead to the introduction of air into the abdominal cavity by direct passage through microscopic diaphragmatic defects or through the media-

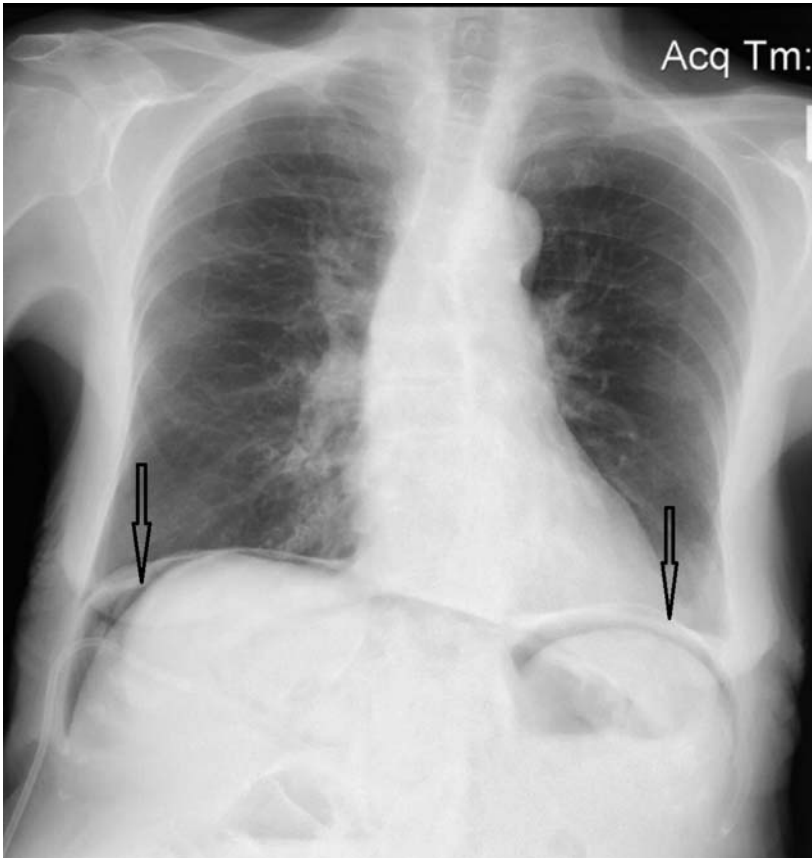


Figure 1. A chest X-ray in case 1 showing pneumoperitoneum (arrows).

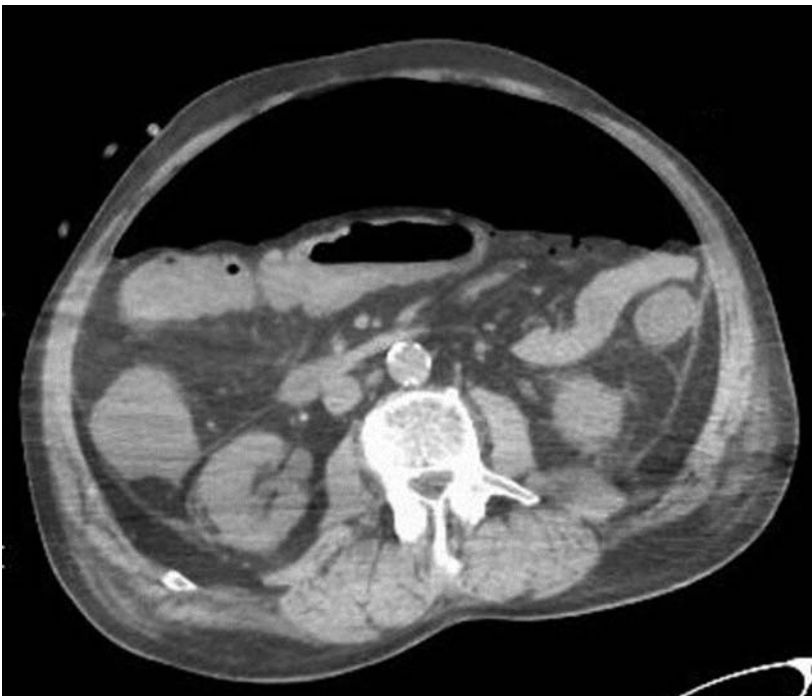


Figure 2. Abdominal computed tomography scan in case 2 showing massive pneumoperitoneum.

stinum along perivascular connective tissue. The risk of pneumoperitoneum during ventilatory support correlates with peak inspiratory pressure above 40 cm of water and positive end-expiratory pressures above 6 cm of water. (9) Clinical decision-making in those cases is hampered by the fact that the patients are ventilated and sedated, thus the compliance of those patients is nil. They often have severe sepsis and multi-organ failure, therefore the decision must be taken immediately and the treatment must be aggressive and brisk. (10) If the origin of sepsis is not intra-abdominal, unnecessary laparotomy often has fatal consequences. (10) Thoracic trauma or barotraumas may cause a rise in intrathoracic pressure and thus result in pneumoperitoneum. Such cases are difficult to manage and create a major surgical dilemma. (11) Pneumoperitoneum may develop following cardiopulmonary resuscitation with or without mouth-to-mouth ventilation. Again, a major dilemma is whether the pneumoperitoneum was caused by viscus perforation or not. Some suggest that if pneumoperitoneum is accompanied by pneumothorax or pneumomediastinum, then a non-operative strategy may be employed. However, pneumomediastinum may accompany gastric perforation, therefore the presence of pneumothorax or pneumomediastinum cannot be taken to exclude visceral perforation. Conversely, the absence of pneumothorax or pneumomediastinum does not indicate that the pneumoperitoneum is the result of visceral perforation. (8)

Generally, any condition associated with increased intra-thoracic pressure can cause non-surgical pneumoperitoneum. (9,10)

B/ Abdominal causes

Pneumoperitoneum following an abdominal surgical procedure is a common finding and expected occurrence. (12,13) Complete resorption of the pneumoperitoneum after laparotomy occurs within the first week in most cases; however it can be recognized on plain abdominal X-ray for up to 4 weeks following laparotomy. (14) In a

laparoscopic approach, the currently preferred gas used for insufflation is carbon dioxide, which is much more rapidly absorbed than room air entering the peritoneal cavity in laparotomy, and thus the pneumoperitoneum after laparoscopic procedures is smaller and of shorter duration. (14,15) Regarding the effect of drains, patients with one or more drains have significantly more often free air in the abdominal cavity than patients without a drain. (14) However, postoperative pneumoperitoneum represents a significant risk as it can mask postoperative complications, such as an anastomotic leak, iatrogenic perforation of the bowel, a postoperative perforated gastroduodenal ulcer, etc. (12,13)

Endoscopic procedures may result in pneumoperitoneum, especially in therapeutic rather than diagnostic endoscopy, e.g. stent placement, stenosis dilatation, excessive air insufflation, excessive electrocautery, polypectomy, mucosectomy, endoscopic submucosal dissection, incautious papillotomy during endoscopic retrograde cholangiopancreatography (ERCP), etc. (16-18) Microperforations may allow air to escape without escape of the intestinal contents. Pneumoperitoneum may be detected in up to 0.1% of endoscopic procedures; (7) it is non-surgical in the majority of cases. However, we must be aware of the fact that "real" perforation may occur in any endoscopic procedure. In ERCP, perforation is seen in 0.3-2.1% of cases. (19) Colonoscopy is complicated by perforation in 0.02 – 3% of cases. (18) Perforation may be discovered immediately during colonoscopy or later on, which is a typical consequence of excessive electrocautery.

The decision between a conservative approach and surgical intervention is very difficult. Any patient with suspected perforation must be monitored closely. Conservative treatment (which includes nil per mouth, parenteral nutrition, hydration, intravenous antibiotics and serial abdominal examination) is advocated in the majority of cases. Surgical intervention is not mandatory for all perforations caused by therapeutic

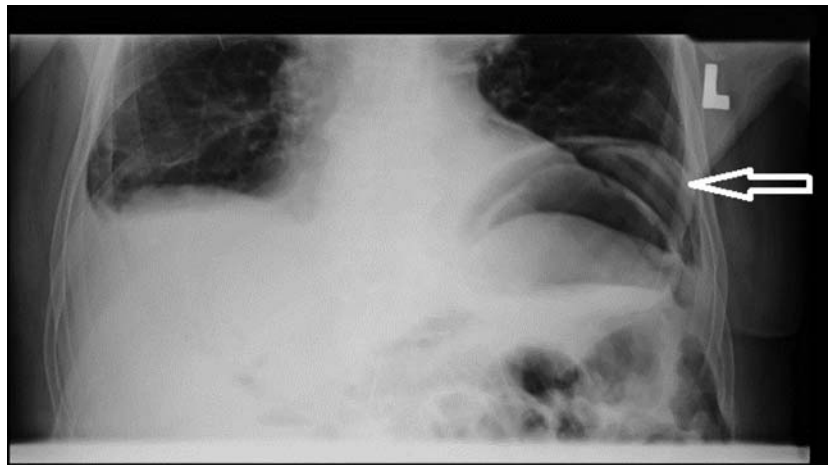


Figure 3. Abdominal X-ray in case 3 showing pneumoperitoneum in left subphrenic area (white arrow).

endoscopic; however, it is indicated in cases with large perforation, in the setting of generalized peritonitis, or ongoing sepsis. (18,19)

Peritoneal dialysis is another condition which can be associated with non-surgical pneumoperitoneum. It is the first choice for patients with end-stage renal disease although it has several limitations. Furthermore, it can be complicated by peritonitis, exit site or tunnel infections, protein malnutrition, hypertension, cardiac failure, haemoperitoneum, etc. Pneumoperitoneum is a complication which occurs approximately in one third of patients. (20,21) The peritoneal dialysis catheter can be an entry for both microorganisms and air into the peritoneal cavity. Therefore, patients may have peritonitis with pneumoperitoneum without viscus perforation. (20) Decision-making and management of these patients is especially difficult. The peritoneal fluid is diluted with the peritoneal catheter fluid; therefore, signs of sepsis are less severe. (22) Unnecessary laparotomy could have fatal consequences for patients with end-stage renal disease. (22) The only advantage of peritoneal dialysis is that the fluid from the peritoneal catheter can be examined. Staphylococcus most likely indicates infection of the peritoneal catheter, which can be treated conservatively. On the other hand, E. coli and G-negative bacteria more likely indicate perforation of the gastrointestinal

tract, a condition requiring immediate treatment. (20) Although the peritoneal catheter is a well-known cause of pneumoperitoneum, the attending physician must be aware at all times. A case of perforated peptic ulcer in a patient with a well-functioning peritoneal catheter has been described. (22)

Percutaneous endoscopic gastrostomy (PEG) is the procedure of choice for establishing enteral access in patients unable to take oral feedings. The reported frequencies of pneumoperitoneum after PEG range from 5% to 20%. (23,24) Serious complications are rare (1-2%). However, misplaced PEGs can lead to hollow viscus perforation with intra-abdominal contamination and subsequent peritonitis along with potentially fatal sepsis. The presence of intra-abdominal air by itself is not an indication for laparotomy. Blum et al. retrospectively analyzed 722 patients who had undergone PEG and only 6 patients had complications requiring laparotomy. They postulated that the presence of intra-abdominal free fluid in addition to the free air is an indication of peritonitis requiring surgical intervention. (23)

Pneumatosis cystoides intestinalis (PCI) is a relatively uncommon condition characterized by the presence of multiple gas-filled cysts within the wall of the gastrointestinal tract. (25) Patients affected by this condition can present with pneumoperitoneum due to the rupture of cysts. Pneumoperitoneum

without peritoneal irritation is thus one of the pathognomonic features. (26) PCI is a radiological or exploratory entity, not a disease; the underlying causes are numerous, including bowel ischemia or obstruction, connective tissue diseases, necrotizing enterocolitis, colonoscopic examination, medication (immunosuppressants, chemotherapy, steroids), obstructive pulmonary disease, etc. (25) If the cause is not known, then PCI is primary or idiopathic. (26) However, the exact aetiology of PCI is unknown. Besides pneumoperitoneum, the condition can be associated with free retroperitoneal air or portal venous air. Pneumoperitoneum is often massive and recurrent. Treatment consists of conservative measures including intravenous fluid, antibiotics, or hyperbaric oxygen therapy. (27) Surgical exploration is unnecessary in the majority of the cases; it is chosen only for complications. (27)

C/ Gynecological causes

In females the natural communication between the fallopian tubes and the peritoneal cavity may predispose to spontaneous pneumoperitoneum following numerous conditions. Patients are often unaware of this communication. A typically young otherwise healthy woman comes to an emergency department complaining of abdominal pain. (28) Pneumoperitoneum is disclosed on X-ray, and this leads to costly and invasive diagnostics, sometimes resulting in unnecessary emergency laparotomy or laparoscopy. Finally, after a thorough discussion of the sexual history of the patient, the cause of the pneumoperitoneum is found. (29)

Coitus has been reported repeatedly in the literature as a cause of non-surgical pneumoperitoneum. (28,30-32) Every physician in an emergency department should be aware of this possibility. As less taboo exists in media and society nowadays, more experimental sexual activities connected with pneumoperitoneum have been reported within the last decades, such as vaginal insufflation. (28,32,33) Embarrassment and modesty often prevent the physicians from asking about the sexual history

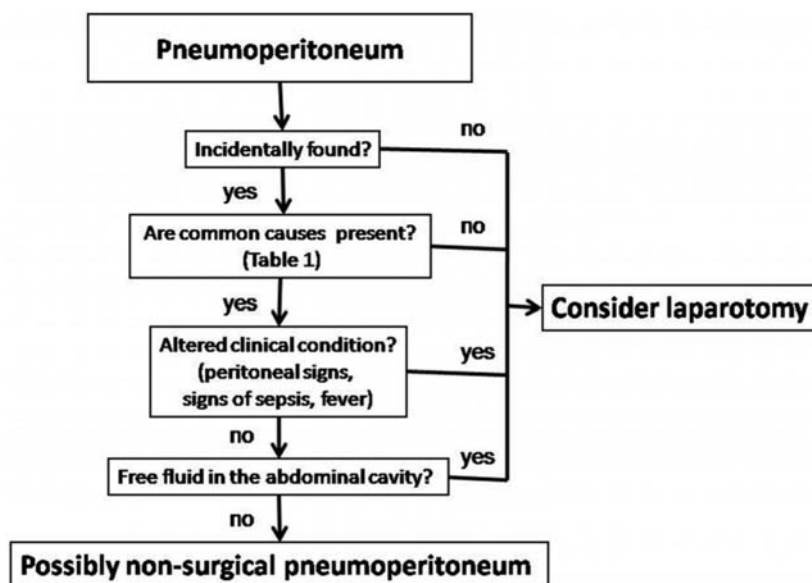


Figure 4. Proposed algorithm how to distinguish between surgical and non-surgical pneumoperitoneum.

of the patient which may lead to unnecessary laparotomy and the correct diagnosis is often obtained afterwards. (28,34) Varon reported an unfortunate case of a patient who underwent even two negative laparotomies before the history of oro-genital insufflation was elicited. (32) Oro-vaginal insufflation resulting in pneumoperitoneum and unnecessary laparotomy is unfortunate, but the main risk of this activity is the more commonly reported fatal air embolism. (35)

Besides sexual activities, other gynecological causes may result in non-surgical pneumoperitoneum, such as vaginal douching, pelvic inflammatory diseases, gynaecological examination procedures, (28) jacuzzi jet, (36) scuba-diving, (37) etc. Air can also enter the abdominal cavity during post-partum knee-chest exercises (38) or exercises in the knee-elbow position. (39) In the latter position, the abdominal viscera fall cranially, therefore negative pressure appears in the pelvis which causes suction. (39) A bizarre case of pneumoperitoneum developing in a young patient bending over to tie her laces has been reported as well. (40)

D/ Other causes

Pneumoperitoneum can have other

causes besides the ones mentioned in table 1. The other causes are rare or even bizarre. They include rare diseases such as emphysematous hepatitis, (41) diseases and conditions which are more common, e.g. systemic sclerosis, (42,43) spontaneous rupture of a pyogenic liver abscess, (44) or cocaine abuse. (45,46)

Occasionally in some cases, the underlying aetiology of the non-surgical pneumoperitoneum is never found and the condition is described as idiopathic. (47,48)

How to distinguish surgical and non-surgical pneumoperitoneum

Even nowadays many physicians are not aware of the possibility that non-surgical pneumoperitoneum could exist, even though it has been described repeatedly in the world literature. (5-8,10-14,17,19-23,26-34,36-50) It is mainly due to the lack of knowledge of the attending physicians which leads to unnecessary laparotomy with possible morbidity. (6) When we acknowledge the possibility of non-surgical pneumoperitoneum, the primary goal is to discern surgical from non-surgical pneumoperitoneum. Identifying cases

in which laparotomy can be avoided is important to prevent unnecessary surgery and its associated morbidity and financial costs. (49) On the other hand, most of the cases of pneumoperitoneum are caused by viscus perforation, most frequently perforation of a gastroduodenal ulcer which leads rapidly to peritonitis and sepsis. Failure to recognize this condition can cause multi-organ failure and death of the patient. Thus in cases of viscus perforation, rapid surgical intervention is mandatory. Distinguishing between surgical and non-surgical pneumoperitoneum is a difficult task for any physician meeting this condition (figure 4). The following guidelines should be adhered to:

1/ Non-surgical pneumoperitoneum is often an incidental finding on chest X-ray performed for other reasons. Thus, incidentally found pneumoperitoneum should not routinely lead to laparotomy.

A large amount of intra-peritoneal gas is typical for non-surgical causes of pneumoperitoneum. In cases of viscus perforation, enteric contamination of the peritoneal cavity develops rapidly, therefore only a small amount of air escapes the hollow organ before the patient is thoroughly examined. In cases of non-surgical pneumoperitoneum, no signs of peritonitis or sepsis are present, therefore more air enters the peritoneal cavity.

2/ The most frequent causes of non-surgical pneumoperitoneum are mentioned in table 1, and when making this difficult decision we should consider them carefully. In some cases the decision is quite clear, e.g. a young, otherwise healthy female of fertile age complaining of pneumoperitoneum after coitus. In other cases, the decision is extremely challenging, e.g. pneumoperitoneum after laparotomy and bowel anastomosis or an endoscopic intervention.

3/ The general condition of the patient and a thorough physical examination are crucial and are often the most important determinants in decision-making. (49) When signs of sepsis such as fever, tachycardia, tachypnoea and leucocytosis are absent, non-surgical pneumoperitoneum should be considered. Not all cases of non-surgical pneumoperitoneum are asymptomatic; abdominal pain could be present in both surgical and non-surgical cases.

4/ When in doubt, CT scan is superior to X-ray in detecting pneumoperitoneum. It can also unveil the underlying aetiology; it can show gas in the portal venous system, foreign bodies, bowel wall masses, and other possible clues. The presence of intraperitoneal fluid usually means intra-abdominal pathology.

Regarding therapy, admitting a patient with pneumoperitoneum to the hospital is advocated in most cases, even if the

cause is thought to be non-surgical. (47) Close observation with repeated evaluation of the patient's general condition is advocated. Prophylactic antibiotics are not necessary. (28) Particular caution must be exercised in regard to patients with immunosuppression, in whom the signs of peritonitis and sepsis may be occult. Puncture of the abdominal cavity with evacuation of pneumoperitoneum should be considered in cases with chronic, long-lasting or massive pneumoperitoneum; in cases of massive or tension pneumoperitoneum and worsening respiratory condition, percutaneous peritoneal cavity drainage can improve cardiopulmonary parameters. (37)

Conclusion

In conclusion, non-surgical pneumoperitoneum is an uncommon but well-known and repeatedly described entity. There are numerous causes of non-surgical pneumoperitoneum apart from hollow viscus perforation. Performing exploratory laparotomy is unnecessary in cases of non-surgical pneumoperitoneum. Also, laparoscopy is an invasive procedure with possible complications and is needless in such cases. The algorithm we propose could be helpful when deciding between surgical and non-surgical causes of pneumoperitoneum.

"The work was supported by MH CZ - DRO (UHHK, 00179906)"

REFERENCES

1. Dandy WE. Pneumoperitoneum: a Method of Detecting Intestinal Perforation-an Aid in Abdominal Diagnosis. *Ann Surg* 1919;70:378-83.
2. Winek TG, Mosely HS, Grout G, Luallin D. Pneumoperitoneum and its association with ruptured abdominal viscus. *Arch Surg* 1988;123:709-12.
3. Stapakis JC, Thickman D. Diagnosis of pneumoperitoneum: abdominal CT vs. upright chest film. *J Comput Assist Tomogr* 1992;16:713-6.
4. Beintaris I, Polymeros D, Papanikolaou IS, Kontopoulou C, Kourikou A, Sioulas AD, et al. Fatal perforation with subcutaneous emphysema complicating ERCP. *Endoscopy* 2012;44 Suppl 2 UCTN:E313-4.
5. Mason JM, Mason EM, Kesmodel KF. Spontaneous pneumoperitoneum without peritonitis and without demonstrable cause. *South Med J* 1946;39:620-4.
6. Freitas Junior WR, Malheiros CA, Kassab P, Ilias EJ. Idiopathic spontaneous pneumoperitoneum. *Rev Assoc Med Bras* 2011;57:614.
7. Mularski RA, Ciccolo ML, Rappaport WD. Nonsurgical causes of pneumoperitoneum. *West J Med* 1999;170:41-6.
8. Williams NM, Watkin DF. Spontaneous pneumoperitoneum and other nonsurgical causes of intraperitoneal free gas. *Postgrad Med J* 1997;73:531-7.
9. Hillman KM. Pneumoperitoneum--a review. *Crit Care Med* 1982;10:476-81.
10. Canivet JL, Yans T, Piret S, Frere P, Beguin Y. Barotrauma-induced tension pneumoperitoneum. *Acta Anaesthesiol Belg* 2003;54:233-6.
11. Krausz M, Manny J. Pneumoperitoneum associated with pneumothorax: a surgical dilemma in the post-traumatic patient. *J Trauma* 1977;17:238-40.
12. Lee CH, Kim JH, Lee MR. Postoperative pneumoperitoneum: guilty or not guilty? *J Korean Surg Soc* 2012;82:227-31.

13. Spinelli N, Nfonsam V, Marcet J, Velanovich V, Frattini JC. Postoperative pneumoperitoneum after colorectal surgery: Expectant vs surgical management. *World J Gastrointest Surg* 2012;4:152-6.
14. Gayer G, Jonas T, Apter S, Amitai M, Shabtai M, Hertz M. Postoperative pneumoperitoneum as detected by CT: prevalence, duration, and relevant factors affecting its possible significance. *Abdom Imaging* 2000;25:301-5.
15. Millitz K, Moote DJ, Sparrow RK, Girotti MJ, Holliday RL, McLarty TD. Pneumoperitoneum after laparoscopic cholecystectomy: frequency and duration as seen on upright chest radiographs. *AJR Am J Roentgenol* 1994;163:837-9.
16. Gasparetto M, Giorgi B, Kleon W, Al Bunni F, Guariso G. Colonic perforation in a child with Crohn's disease: successful medical treatment rescues from colectomy. *Case Rep Gastrointest Med* 2012;2012:152414.
17. Makni A, Chebbi F, Ben Safta Z. Pneumoretroperitoneum, bilateral pneumothorax and emphysema following endoscopic biliary sphincterotomy. *Acta Chir Belg* 2012;112:307-9.
18. Sagawa T, Kakizaki S, Iizuka H, Onozato Y, Sohara N, Okamura S, et al. Analysis of colonoscopic perforations at a local clinic and a tertiary hospital. *World J Gastroenterol* 2012;18:4898-4904.
19. Fujii L, Lau A, Fleischer DE, Harrison ME. Successful Nonsurgical Treatment of Pneumomediastinum, Pneumothorax, Pneumoperitoneum, Pneumoretroperitoneum, and Subcutaneous Emphysema following ERCP. *Gastroenterol Res Pract* 2010;2010:289135.
20. Ionescu C, Ecobici M, Olaru D, Stanescu C, Lupescu I, Voiculescu M. Pneumoperitoneum--rare complication in end stage renal disease patient on automated peritoneal dialysis. *Rom J Intern Med* 2008;46:351-5.
21. Kiefer T, Schenk U, Weber J, Hubel E, Kuhlmann U. Incidence and significance of pneumoperitoneum in continuous ambulatory peritoneal dialysis. *Am J Kidney Dis* 1993;22:30-5.
22. Huang JW, Peng YS, Wu MS, Tsai TJ. Pneumoperitoneum caused by a perforated peptic ulcer in a peritoneal dialysis patient: difficulty in diagnosis. *Am J Kidney Dis* 1999;33:e6.
23. Blum CA, Selander C, Ruddy JM, Leon S. The incidence and clinical significance of pneumoperitoneum after percutaneous endoscopic gastrostomy: a review of 722 cases. *Am Surg* 2009;75:39-43.
24. Wiesen AJ, Sideridis K, Fernandes A, Hines J, Indaram A, Weinstein L, et al. True incidence and clinical significance of pneumoperitoneum after PEG placement: a prospective study. *Gastrointest Endosc* 2006;64:886-9.
25. Cyrany J, Kopacova M, Rejchrt S, Ryska A, Dvorak P, Brozik J, et al. Pneumatosis cystoides intestinalis. *Acta Endosc* 2011;41:243-52.
26. Arikanoğlu Z, Aygen E, Camci C, Akbulut S, Basbug M, Dogru O, et al. Pneumatosis cystoides intestinalis: a single center experience. *World J Gastroenterol* 2012;18:453-7.
27. Azzaroli F, Turco L, Ceroni L, Galloni SS, Buonfiglioli F, Calvanese C, et al. Pneumatosis cystoides intestinalis. *World J Gastroenterol* 2011;17:4932-6.
28. Jacobs VR, Mundhenke C, Maass N, Hilpert F, Jonat W. Sexual activity as cause for non-surgical pneumoperitoneum. *Jsls* 2000;4:297-300.
29. Lovecek M, Herman J, Svach I, Gryga A, Duda M. Postcoital pneumoperitoneum after hysterectomy. *Surg Endosc* 2001;15:98.
30. Spaulding LB, Gallup DG. Pneumoperitoneum after hysterectomy. *Jama* 1979;241:825.
31. Tabrisky J, Mallin LP, Smith JA, 3rd. Pneumoperitoneum after coitus. A complication due to uterine tube prolapse after vaginal hysterectomy. *Obstet Gynecol* 1972;40:218-20.
32. Varon J, Laufer MD, Sternbach GL. Recurrent pneumoperitoneum following vaginal insufflation. *Am J Emerg Med* 1991;9:447-8.
33. Daly BD, Guthrie JA, Couse NF. Pneumoperitoneum without peritonitis. *Postgrad Med J* 1991;67:999-1003.
34. Gantt CB, Jr., Daniel WW, Hallenbeck GA. Nonsurgical pneumoperitoneum. *Am J Surg* 1977;134:411-4.
35. Lyness JR, Bentley AJ. Air embolism during sexual intercourse in the puerperium. *Am J Forensic Med Pathol* 2010;31:247-9.
36. Williams TC, Kanne JP, Lalani TA. Jacuzzi jet-induced pneumoperitoneum. *Emerg Radiol* 2004;10:259-61.
37. Bunni J, Bryson PJ, Higgs SM. Abdominal compartment syndrome caused by tension pneumoperitoneum in a scuba diver. *Ann R Coll Surg Engl* 2012;94:e237-9.
38. Dodek SM, Friedman JM. Spontaneous pneumoperitoneum. *Obstet Gynecol* 1953;1:689-98.
39. Lozman H, Newman AJ. Spontaneous pneumoperitoneum occurring during postpartum exercises in the knee-chest position. *Am J Obstet Gynecol* 1956;72:903-5.
40. Wright AR. Spontaneous pneumoperitoneum. *AMA Arch Surg* 1959;78:500-2.
41. Kim JH, Jung ES, Jeong SH, Kim JS, Ku YS, Hahm KB, et al. A case of emphysematous hepatitis with spontaneous pneumoperitoneum in a patient with hilar cholangiocarcinoma. *Korean J Hepatol* 2012;18:94-7.
42. London NJ, Bailey RG, Hall AW. Spontaneous benign pneumoperitoneum complicating scleroderma in the absence of pneumatosis cystoides intestinalis. *Postgrad Med J* 1990;66:61-2.
43. Vischio J, Matlyuk-Urman Z, Lakshminarayanan S. Benign spontaneous pneumoperitoneum in systemic sclerosis. *J Clin Rheumatol* 2010;16:379-81.
44. Ukikusa M, Inomoto T, Kitai T, Ino K, Higashiyama H, Arimoto A, et al. Pneumoperitoneum following the spontaneous rupture of a gas-containing pyogenic liver abscess: report of a case. *Surg Today* 2001;31:76-9.
45. Andreone P, L'Heureux P, Strate RG. An unusual cause of massive non-surgical pneumoperitoneum: case report. *J Trauma* 1989;29:1286-8.
46. Uva JL. Spontaneous pneumothoraces, pneumomediastinum, and pneumoperitoneum: consequences of smoking crack cocaine. *Pediatr Emerg Care* 1997;13:24-6.
47. Clements WD, Gunna BR, Archbold JA, Parks TG. Idiopathic spontaneous pneumoperitoneum--avoiding laparotomy--a case report. *Ulster Med J* 1996;65:84-6.
48. Masood QF, Khaleeq T, Khan Q, Abbasi S, Arshad S, Bano F, et al. A case of non-surgical pneumoperitoneum: gas under the diaphragm. *J Ayub Med Coll Abbottabad* 2009;21:176-7.
49. Brill SE, Skipworth J, Stoker DL. Conservative management of pneumatosis intestinalis and massive pneumoperitoneum in the acute abdomen: a case report. *Ann R Coll Surg Engl* 2008;90:W11-3.
50. Freeman RK. Pneumoperitoneum from oral-genital insufflation. *Obstet Gynecol* 1970;36:162-4.