

CASE REPORT

Cardiac tamponade as an unusual initial presentation of squamous cell carcinoma of the esophagus

Nitchakarn Hongsuphan¹, Saowaluck Faikongngeon¹, Wachira Wongtanasarsin^{1,*}

¹Department of Emergency Medicine,
Faculty of Medicine, Chiang Mai
University, 50200 Chiang Mai, Thailand

***Correspondence**wachir_w@hotmail.com

(Wachira Wongtanasarsin)

Abstract

Pericardial effusions leading to cardiac tamponade have previously been described with esophageal cancer. However, up to eighty percent of these cases have been reported in association with chemotherapy and radiation. Patients with esophageal cancer seldom initially present with pericardial effusion resulting from esophageal pericardial fistula (EPF). Herein, we present the case of a 62-year-old man who presented with pericardial effusion with an unknown etiology at presentation. Subsequently, the patient developed cardiac tamponade and was referred to the tertiary hospital for further evaluation. Computed tomography of the chest revealed a circumferential irregular enhancing lesion at the mid-thoracic esophagus suspecting esophageal cancer with EPF and a moderate amount of pericardial effusion. The patient underwent esophagoscopy and squamous cell carcinoma was found from the esophageal biopsy. An esophageal stent was successfully placed to conceal the perforation. Eventually, the patient died 13 days after admission complicated by refractory septic shock. This case highlights an atypical presentation of esophageal cancer and an unusual cause of cardiac tamponade.

Keywords

Cardiac tamponade; Esophageal cancer; Pericardial effusion; Esophagus; Esophageal pericardial fistula

1. Introduction

Cardiac tamponade is considered a life-threatening condition leading to hemodynamic abnormalities. Common causes of cardiac tamponade include pericarditis, tuberculosis, iatrogenic, trauma, and malignancy [1]. However, some uncommon conditions could possibly result in cardiac tamponade. Esophageal cancer has been reported to be related with pericardial effusion or cardiac tamponade [2]. Esophago-pericardial fistula (EPF) is a rare and life-threatening condition, which mostly occurs after a benign esophageal disease associated with an esophageal ulcer or esophagitis. Still, nearly one-fourth of all EPFs were reported to be connected with malignancy [2, 3]; most of these cases were squamous cell carcinoma (SCC) of the esophagus [2]. Nevertheless, there are many mechanisms linked to the development of EPF after the SCC of the esophagus: direct invasion of the tumor, metastasis, post-radiation, and post-chemotherapy [4, 5]. Interestingly, esophageal cancers can also present with cardiac tamponade and esophageal rupture with EPF as an initial presentation [2]. Despite early surgical drainage of pericardial fluid, patients with EPF related to malignancy often have a particularly poor prognosis [1, 2, 6, 7].

2. Case presentation

A 62-year-old man with underlying diseases of dyslipidemia, hypertension, and stage III-chronic renal insufficiency was referred to our hospital for definite diagnosis and further management. The patient initially presented at the primary hospital with complaints of high-grade fever, cough, and dyspnea. As a result, the patient was primarily diagnosed with bacterial pneumonia with septic shock. Two days after admission to the primary hospital, the patient developed acute respiratory failure and was subsequently intubated. To evaluate the possible causes of acute respiratory failure, bedside transthoracic echocardiography (TTE) was performed and revealed a large pericardial effusion (3.2 cm). The patient was then referred to our hospital for further evaluation by an attending cardiologist. A review of systems was positive for dysphagia and odynophagia without a history of aspiration about a month before admission. At the presentation at the emergency department (ED), the patient was found to be in shock with tachycardia and hypotension. His physical examination revealed a man with intubation. His blood pressure was 86/64 mmHg, pulse 150 beats per minute, and temperature of 37.8 degree Celsius. Respiratory examination revealed rhonchi at bilateral lung fields. The cardiovascular system revealed a distant heart sound with diffuse apex. No jugular venous distension was detected. The patient was initially resuscitated with 1000

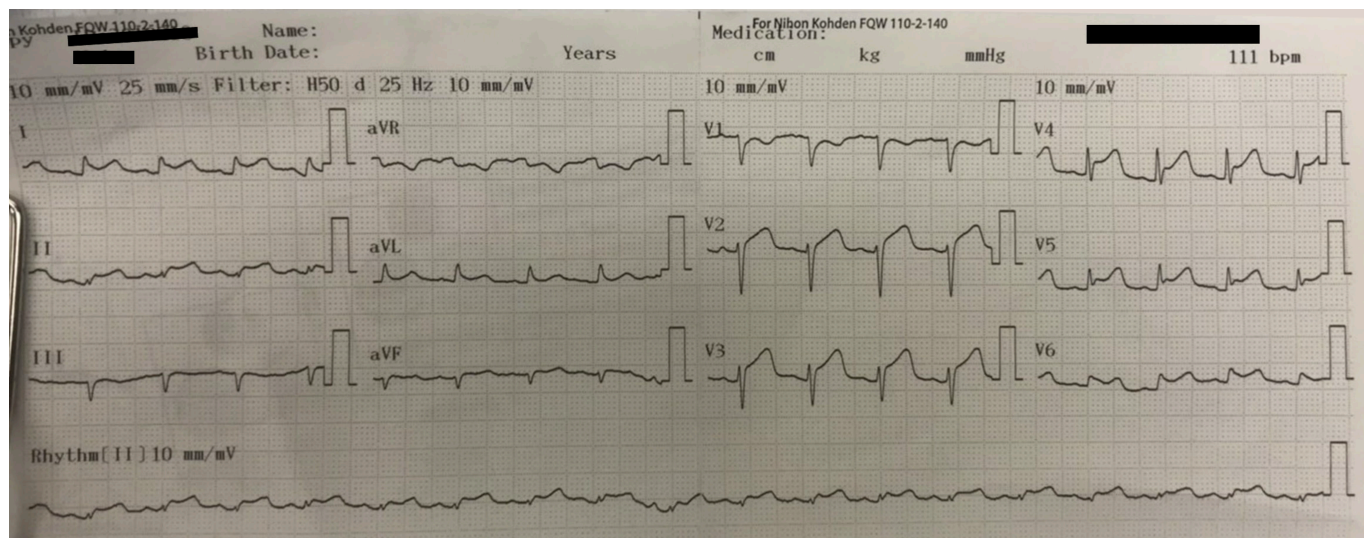


FIGURE 1. A 12-lead electrocardiogram of the patient showed sinus tachycardia, diffused ST-segment elevations, and generalized low voltage QRS complexes.

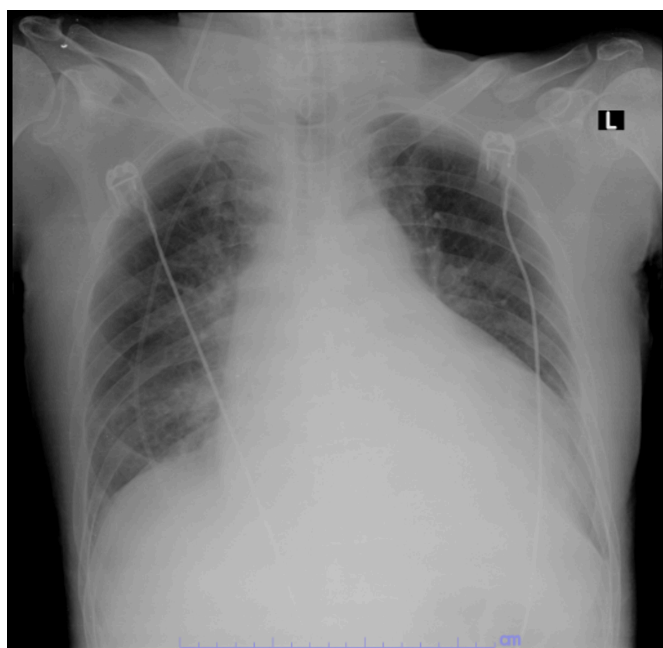


FIGURE 2. A chest X-ray revealed cardiomegaly with a widening of the mediastinum and haziness at bilateral lung fields.

mL of normal saline. Still, his condition did not improve. Nevertheless, after administering norepinephrine, the patient's condition improved, and his blood pressure increased.

Laboratory results at our hospital were notable for leukocytosis (White Blood Cell (WBC) of 38,860 cells per mm^3 with 93.7% of neutrophil), hypocalcemia (7.6 mg/dL), hypoalbuminemia (2.0 g/dL), lactic acid 2.62 mmol/L, and C-reactive protein 331.7 mg/L. Other lab results were unremarkable, including cardiac enzymes and liver function tests. A 12-lead electrocardiogram showed diffused ST-segment elevations, generalized low voltages, and electrical alternans (Fig. 1). A chest X-ray revealed cardiomegaly with a widening of the mediastinum and haziness at both lungs (Fig. 2). Bed-

side TTE revealed large circumferential pericardial effusion, 3.3 cm in maximum thickness, with tamponade physiology. Concerning the etiology of cardiac tamponade, computed tomography (CT) of the chest with contrast media was requested, which demonstrated a circumferential irregular enhancing lesion at the mid-thoracic esophagus. It also revealed a moderate amount of pericardial effusion and bilateral pleural and heterogeneous enhancement of right lower lung parenchyma (Fig. 3). Consequently, cardiac tamponade was diagnosed due to an esophageal perforation secondary to esophageal cancer. An attending cardiologist was emergently consulted, and the patient subsequently underwent emergency pericardiocentesis at the ED. Pericardial fluid was turbid yellow and showed acute inflammation profile (WBC of 44,006 cells per mm^3 with 99% neutrophil and 1% monocyte, no bacterial growth, and AFB stain was negative). In addition, we retrospectively reviewed any cultures obtained at the primary hospital (sputum and blood cultures) and found that they were negative for both types of specimens. Intercostal drainages were placed on both sides of the chest. Esophagoscopy revealed an eccentric intraluminal esophageal tumor and squamous cell carcinoma was found from the esophageal biopsy. Afterward, a right pericardial window was performed on the patient to remove and drain pericardial fibrin and clots. An esophageal stent was successfully placed to conceal the perforation. His hospital course was complicated by septic shock, and he passed away 13 days after hospital admission.

3. Discussion

Pericardial effusion and cardiac tamponade have been reported in association with several cancers including esophageal cancers [2]. Yet, most of the cases have been documented in association with chemotherapy, radiation, and stenting [2, 3, 8]. This case highlights the rare initial presentation of esophageal cancer as the culprit lesion in causing pericardial effusion and cardiac tamponade.

To date, up to 80 cases of EPF have been reported and

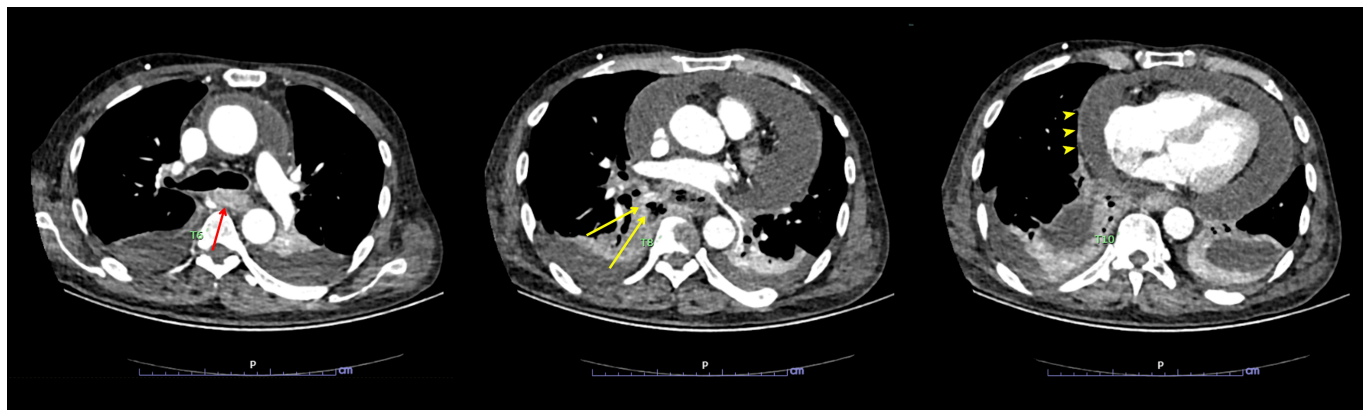


FIGURE 3. CT of the chest (axial view) showing a circumferential thickening lesion at mid-thoracic esophagus about level of T6 spine (red arrow), measuring $1.9 \times 4.2 \times 3.0$ cm in maximal axial and vertical diameters, with track-like lesion extending from the right side of this lesion containing fluid and multiple air bubbles contiguous from the right side of the esophagus (yellow arrows). Also, a moderate amount of pericardial effusion with thin smooth enhancing wall (arrowheads), measuring 2.7 cm in thickness.

published in the literature. Yet, benign esophageal diseases account for the most common explanation for the cases [8]. In 2019, Abdullah *et al.* [2] came up with a comprehensive literature review presenting seven cases of cardiac tamponade as an initial presentation of esophageal cancer in the setting of an EPF. All of them were over 50 years old (ranging from 52–71) and six of them were male. The initial presentations are usually nonspecific before the event of tamponade [4]. The earliest signs are chest discomfort and abnormalities on electrocardiography [4]. All cases were diagnosed with SCC from the tissue biopsy. Urgent decompression of the cardiac tamponade was needed in all previous cases, then followed by placement of a pericardial window and pericardiectomy [2]. All of them also had purulent pericarditis with various types of *Streptococcus spp.*, including community-acquired Methicillin-resistant *Staphylococcus aureus* (MRSA) [2]. Every case visualized EPF by either endoscope or esophagogram and an esophageal stent was placed in most cases [2]. Compared to the previous cases, our case had many things in common such as age above 50 years old, male gender, and histology of cancer. Esophageal cancer tends to be found higher in an old age male [9]. Furthermore, all tissue pathologies of the cases, including ours, were SCC. Patients with SCC are more likely to be asymptomatic until the advanced stage or the development of complications. On the other hand, patients with adenocarcinoma usually present earlier due to the mechanism of adenocarcinoma which evolved from premalignant lesions [10]. Moreover, SCC is a mass-forming type of cancer cell; it tends to be more locally invasive [2]. Interestingly, no organism was identified from the specimen in this case. This might have resulted from the antibiotics given to treat the pre-diagnosed pericarditis and cardiac tamponade from the primary hospital. In an aspect of the prognosis, most of them died within days to weeks after initial presentation. The possible explanation behind this could be the unusual presentations of this disease and also the aggressiveness of SCC [2].

4. Conclusions

Most pericardial effusions leading to a cardiac tamponade have been antecedently reported in association with chemotherapy and radiation. However, this case highlights the association between cardiac tamponade and the SCC of the esophagus. Therefore, CT could be helpful in identifying the etiology of cardiac tamponade in these cases. Patients with cardiac tamponade normally need an urgent cardiac decompression. Subsequent pericardial window and pericardiectomy and stenting help manage these patients. However, they tend to possess an unfavorable outcome with most of them passing away days to weeks after diagnosis.

AUTHOR CONTRIBUTIONS

NH, SF, and WW conceived and designed the study and contributed to the emergency management of the patient. NH drafted the initial article. WW edited and revised the manuscript. All authors read and approved the latest version of the manuscript.

ETHICS APPROVAL AND CONSENT TO PARTICIPATE

Our work does not infringe on any rights of others, including privacy rights, and intellectual property rights. There is no human rights violation in our manuscript. The patient provided written informed consent for publication of this case. Our institution provided an exemption for consideration since it was a case report article with permission from the patient.

ACKNOWLEDGMENT

We gratefully acknowledge Ms. Thanchanok Srisawang and Mrs. Barbara Metzler for their elaborative language editing on the manuscript. We also thank the Research Unit of Department of Emergency Medicine, Chiang Mai University for

providing conveniences to preparation of this manuscript.

FUNDING

This research received no external funding.

CONFLICT OF INTEREST

The authors declare no conflict of interest. Wachira Wongtanasarasin is a Guest Editor of this journal.

DATA AVAILABILITY

The data used to support the findings of this study are available from the corresponding author upon request.

CONSENT TO PARTICIPATE

The authors guarantee that they have acquired all appropriate patient consent forms. In the form, the patient and patient's relatives have given their consent for the images and other clinical information to be reported in the journal. The patient and patient's relatives understand that name and initials will not be published, and due efforts will be performed to conceal identity, but anonymity cannot be confirmed.

REFERENCES

- [1] Adler Y, Charron P. The 2015 ESC Guidelines for the diagnosis and management of pericardial diseases. *European Heart Journal*. 2015; 36: 2873–2874.
- [2] Abdullah HMA, Khan UI, Wasekar C, Omar M. Cardiac tamponade and purulent pericarditis secondary to an oesophageal pericardial fistula as an

initial presentation of squamous cell carcinoma of the oesophagus. *BMJ Case Reports*. 2019; 12: e229634.

- [3] Saluja SS, Puri SK, Arora A, Chander Sharma B, Mishra PK. Esophagopericardial fistula: a delayed complication after esophageal stenting. *the American Surgeon*. 2013; 79: 550–552.
- [4] Touati GD, Carmi D, Nzomvuama A, Marticho P. Purulent pericarditis caused by malignant oesophago-pericardial fistula. *European Journal of Cardio-Thoracic Surgery*. 2003; 24: 847–849.
- [5] Kaufman J, Thongsuwan N, Stern E, Karmy-Jones R. Esophageal-pericardial fistula with purulent pericarditis secondary to esophageal carcinoma presenting with tamponade. *The Annals of Thoracic Surgery*. 2003; 75: 288–289.
- [6] Tombazzi C, Marino G, Yong J, Vallejo V, Reddy K. Malignant esophageal pericardial fistula presenting as cardiac tamponade. *Digestive Diseases and Sciences*. 2006; 51: 1290–1293.
- [7] Kariyanna PT, Jayarangaiah A, Pedalino R, Hegde S, Marmur JD, Shenoy A, *et al*. Esophago-pericardial Fistula Induced Community Acquired Methicillin Resistant Staphylococcus Aureus (CA-MRSA) Cardiac Tamponade—a Rare Case Report and Literature Review. *American Journal of Medical Case Reports*. 2018; 6: 109–113.
- [8] Wang M-C, Huang B-H, Kok VC. Esophagopericardial fistula and purulent pericarditis causing cardiac tamponade during concurrent chemoradiotherapy for esophageal cancer: A case report. *Therapeutic Radiology and Oncology*. 2017; 24: 67–75.
- [9] Chen R, Zheng RS, Zhang SW, Zeng HM, Wang SM, Sun KX, *et al*. Analysis of incidence and mortality of esophageal cancer in China, 2015. *Zhonghua Yu Fang Yi Xue Za Zhi*. 2019; 53: 1094–1097. (In Chinese)
- [10] Zarean E, Mahmoudi M, Azimi T, Amini P. Determining Overall Survival and Risk Factors in Esophageal Cancer Using Censored Quantile Regression. *Asian Pacific Journal of Cancer Prevention*. 2018; 19: 3081–3086.

How to cite this article: Nitchakarn Hongsuphan, Saowaluck Faikongneon, Wachira Wongtanasarasin. Cardiac tamponade as an unusual initial presentation of squamous cell carcinoma of the esophagus. *Signa Vitae*. 2022; 18(6): 110-113. doi:10.22514/sv.2021.120.