

CASE REPORT

Liver abscess presenting with dyspnea and right-side neck pain that can be overlooked in the emergency department: a case report

Sangun Nah¹, Young Soon Cho^{1,*}, Sangsoo Han^{1,*},†

¹Department of Emergency Medicine, Soonchunhyang University Bucheon Hospital, 14584 Bucheon, Republic of Korea

***Correspondence**emer0717@gmail.com

(Young Soon Cho);

brayden0819@daum.net

(Sangsoo Han)

† These authors contributed equally.

Abstract

Liver abscess is a potentially fatal mass associated with liver injury and disease with a mortality rate of 12% if treatment is delayed. Patients usually complain of fever or upper abdominal pain; however, atypical symptoms, such as right shoulder pain, may also appear. We report a case of liver abscess presenting as dyspnea and right-side neck pain without any other symptoms. A 78-year-old man visited the hospital complaining of right-side neck pain, which had persisted for 10 days, and dyspnea that developed over time. The neck pain and dyspnea were aggravated with changes in posture. Arterial blood gas results (pH 7.47, PO₂ 76 mmHg, PCO₂ 33 mmHg, SpO₂ 98%) and chest and neck X-rays were normal, but white blood cell and C-reactive protein levels were higher than normal. A contrast-enhanced computed tomography scan of the chest was performed to differentiate the unexplained dyspnea and neck pain, and the liver abscess, which was diagnosed accidentally. Clinicians should consider liver abscess as a differential diagnosis in patients with dyspnea or neck pain when there is an increase in inflammatory marker, but it is difficult to explain the cause.

Keywords

Liver abscess; Phrenic nerve; Dyspnea; Neck pain; Referred pain

1. Introduction

A liver abscess is a lump of pus formed inside the liver caused by liver injury, direct contact with a biliary tract infection, or leakage from another intraperitoneal abscess via the portal vein [1]. The most common risk factor is diabetes mellitus (DM), and other risk factors include malignancy, liver cirrhosis, and biliary or pancreatic disease. The current mortality rate from a liver abscess is 0.5–4% (owing to the development of effective drainage methods and antibiotics against specific microorganisms), but if treatment is delayed it rises to 12% [1]. The representative symptoms of liver abscess are fever or upper abdominal pain, which occur in about 90% of patients [2]. Other symptoms include chills, nausea or vomiting, and atypical symptoms such as hiccups or right shoulder pain [1, 3].

We report a case of liver abscess presenting with dyspnea and neck pain, which are different from the previously known atypical symptoms.

2. Case presentation

A 78-year-old man visited the hospital complaining of right-side neck pain and dyspnea, and he stated that he had no fever before the presentation. The patient had developed persistent right-side neck pain for 10 days, and was taking a nonsteroidal anti-inflammatory drug (NSAID). However, no

improvement in the neck pain was observed and the newly developed dyspnea persisted for 2 days. The patient was a non-smoker and did not drink alcohol regularly. And he had no specific traumatic history had DM and hypertension.

The initial vital signs were blood pressure 160/100 mmHg, body temperature 36.8 °C, heart rate 68 bpm, respiratory rate 21 bpm, and SpO₂ 98%. He complained of tingling pain from the right side of the neck to the right shoulder and his numerical rating scale for pain was 5. Dyspnea improved in the sitting position but worsened in the supine or right lateral recumbent position, and the pain had the same pattern. No tenderness was detected at the site of the self-reported pain. Laboratory findings were white blood cells 17,680/mm³, C-reactive protein 18.06 mg/dL, brain natriuretic peptide 170 pg/mL, troponin T 0.006 ng/mL, aspartate transaminase 37 U/L, alanine transaminase 17 U/L, alkaline phosphatase 217 U/L, and total bilirubin 1.83 mg/dL; arterial blood gas pH 7.47, PO₂ 76 mmHg and PCO₂ 33 mmHg. No abnormalities were detected in chest, shoulder, and neck X-rays, and electrocardiography indicated a normal sinus rhythm. A neck-chest contrast-enhanced computed tomography (CT) scan was performed; an about 8.3 cm peripheral enhancing septated mass was found in liver segments 2, 3, and 4 in the chest CT, so the patient was admitted to the gastroenterology department under the diagnosis of a liver abscess (Fig. 1A,B). Ultrasound-

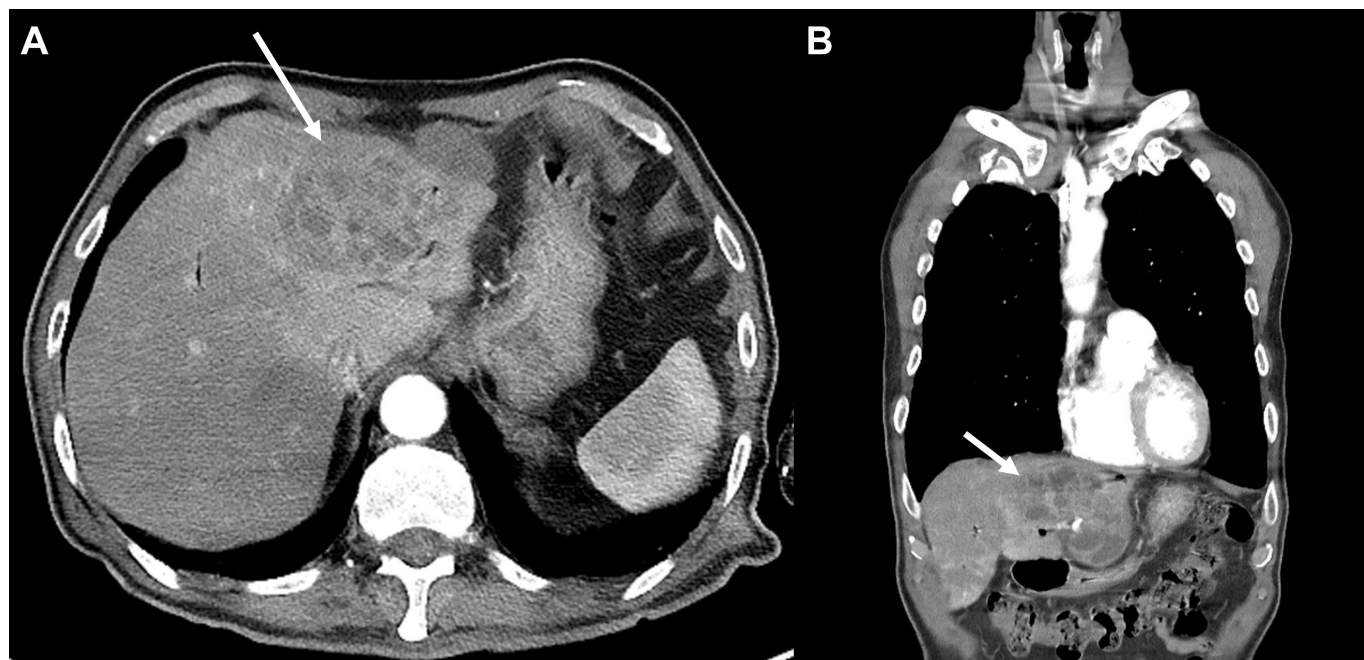


FIGURE 1. Contrast-enhanced computed tomography scan of the 8.3 cm liver abscess in segments 2, 3, and 4. (A) Horizontal view; (B) coronal view.

TABLE 1. Summary of clinical information of five cases reported as phrenic nerve irritation caused by a liver abscess.

Author	Sex/age	Clinical presentation and symptoms
Lee <i>et al.</i> [3]	Male/56	Hiccups, fever, tachycardia, and right shoulder pain
Park <i>et al.</i> [5]	Male/31	Right shoulder and posterior neck pain
Subramaniyam <i>et al.</i> [7]	Male/mid-40s	Fever and right-sided neck pain
Williams <i>et al.</i> [6]	Male/18	Abdominal, shoulder pain, fever, night sweats, weight loss, and malaise
Present case	Male/78	Dyspnea and right-side neck pain

guided percutaneous drainage was performed, and a percutaneous catheter was inserted. The abscess culture yielded *Klebsiella pneumoniae*. The patient discharged on day 11 of hospitalization after removing the percutaneous catheter. The dyspnea and neck pain gradually improved. There were no unusual findings at follow-up 2 weeks later.

3. Discussion

We report a patient with liver abscess who complained of dyspnea and right-side neck pain. These symptoms are thought to have been caused by irritation of the phrenic nerve due to the liver abscess, which was located in the sub-diaphragmatic area. According to previous reports, atypical symptoms such as right shoulder pain can occur when phrenic nerve is irritated by a liver abscess [1, 4]. Five cases of phrenic nerve irritation caused by a liver abscess, including our case, are presented in Table 1 (Ref. [3, 5–7]). Common symptoms of liver abscess are fever and/or abdominal pain. However, in our case, there were only accompanying neck pain and dyspnea, revealing a different pattern from previous reports.

The phrenic nerve, which is a sensory/motor nerve from the C3–5 spinal nerve, innervates the central tendon of the diaphragm, the pericardium (the membrane lining the heart), and the outer lining in the medial region of the lungs (parietal

pleura), sending sensory information to the brain [8]. The phrenic nerve is important because it plays a critical role in breathing by controlling the diaphragm [4]. Therefore, respiratory dysfunction can occur when this nerve is injured or irritated. This respiratory dysfunction can occur by stimulating the diaphragm with compression, infection, or trauma, and can cause patients to complain of symptoms such as orthopnea, dyspnea, and cough [9]. In our case also, the liver abscess stimulated the diaphragm, which may have contributed to the patient's dyspnea. The irritation of phrenic nerve may cause specific referred pain such as shoulder pain [1, 3, 5]. Well-known examples of such pain include Kehr's sign caused by injury or disease to the spleen [5]. Such pain is caused by a projection to a somatic area innervated by the same spinal segment where the nerve irritation occurs [10, 11]. In our case, the liver abscess irritated the phrenic nerve located in the diaphragm, so the right-side neck pain may have been caused by the same spinal nerve supply (C3–5) shared by the phrenic and somatic nerves. However, if the abscess was remote from the liver capsule, the symptoms due to phrenic nerve irritation would not be to occur.

Klebsiella pneumoniae infection may occur in patients with predisposing factors like DM or alcohol use disorder [12]. In patient with liver abscess caused by *Klebsiella pneumoniae*, cervical epidural abscess might be considered if the patient

complains of neck pain [13]. In our case, although the patient had DM, cervical epidural abscess did not develop.

In summary, it is uncommon for a patient with a liver abscess to complain of dyspnea or right-side neck pain without any other symptoms. In our case, it is thought that the symptoms commonly associated with liver abscess, such as fever and abdominal pain, were masked by the NSAID that the patient was taking. Clinicians should consider a liver abscess in patients with dyspnea and/or neck pain when there is an increase in inflammatory marker, but it is difficult to explain the cause.

AUTHOR CONTRIBUTIONS

SN examined the patient and diagnosed the case. SN wrote the first version of the manuscript. YSC and SH approved the final version of the paper and edited it. All authors contributed to the final version of the manuscript.

ETHICS APPROVAL AND CONSENT TO PARTICIPATE

The study protocol was approved by the Institutional Review Board of Soonchunhyang University Bucheon Hospital (IRB file no. 2021-05-035). Informed consent was obtained from the patient involved in the study.

ACKNOWLEDGMENT

Thanks to all the peer reviewers for their opinions and suggestions.

FUNDING

This research was funded by the Soonchunhyang University Research Fund, grant number 10210044.

CONFLICT OF INTEREST

The authors declare no conflict of interest.

REFERENCES

- [1] Kavaliauskaitė A, Buginytė R. Pyogenic liver abscess: literature review. *Pathogenesis*. 2021; 2: 8.
- [2] Albenmoussa A, Sanai FM, Singhal A, Babatin MA, AlZanbagi AA, Al-Otaibi MM, *et al*. Liver abscess presentation and management in Saudi Arabia and the United Kingdom. *Annals of Saudi Medicine*. 2011; 31: 528–532.
- [3] Lee C-C, Chang W-K. Liver abscess presenting with persistent hiccups and right shoulder pain. *QJM: An International Journal of Medicine*. 2020; 113: 203–204.
- [4] Dupont G, Tubbs RS. The Phrenic Nerve. *Surgical Anatomy of the Cervical Plexus and its Branches* (pp. 31–41). Elsevier: Amsterdam, The Netherlands. 2022.
- [5] Park SH, Lee PB, Seo MS, Lim YH, Oh YS. Referred Shoulder Pain due to Liver Abscess -a case report. *The Korean Journal of Pain*. 2005; 18: 267–270.
- [6] Williams R, Larson NS, Pinsker JE. Occult pyogenic liver abscess in an adolescent with type 2 diabetes. *Endocrine*. 2014; 45: 335–336.
- [7] Subramaniyam V, Saito A, Tokushige K. Liver abscess due to *Fusobacterium* species detected on ultrasonography: a case report. *Journal of Medical Ultrasonics*. 2018; 45: 623–627.
- [8] Kokatnur L, Rudrappa M. Diaphragmatic Palsy. *Diseases*. 2018; 6: 16.
- [9] Bektas F, Soyuncu S. Diaphragmatic irritation caused by nail-gun: an unusual cause of bradycardia/Civi tabancasina bagli diyafram irritasyonu: bradikardinin nadir bir nedeni. *Academic Emergency Medicine*. 2012; 11: 243–245.
- [10] Blair RW, Weber RN, Foreman RD. Responses of thoracic spinothalamic neurons to intracardiac injection of bradykinin in the monkey. *Circulation Research*. 1982; 51: 83–94.
- [11] Hobbs SF, Chandler MJ, Bolser DC, Foreman RD. Segmental organization of visceral and somatic input onto C3-T6 spinothalamic tract cells of the monkey. *Journal of Neurophysiology*. 1992; 68: 1575–1588.
- [12] Abdul-Hamid A, Bailey S. *Klebsiella pneumoniae* liver abscess and endophthalmitis. *BMJ Case Reports*. 2013; 2013: bcr2013008690.
- [13] Hsieh M, Lu T, Ma MH, Wang H, Chen S. Unrecognized cervical spinal epidural abscess associated with metastatic *Klebsiella pneumoniae* bacteremia and liver abscess in nondiabetic patients. *Diagnostic Microbiology and Infectious Disease*. 2009; 65: 65–68.

How to cite this article: Sangun Nah, Young Soon Cho, Sangsoo Han. Liver abscess presenting with dyspnea and right-side neck pain that can be overlooked in the emergency department: a case report. *Signa Vitae*. 2023; 19(1): 157-159. doi: 10.22514/sv.2021.213.