

CASE REPORT

Sympathetic nerve entrapment point injection for intractable nausea and vomiting in pregnancy: a case report

Sungwoo Choi^{1,†}, Kangho Kim^{2,†}, Sangun Nah¹, Sechan Kim¹, Sangsoo Han^{1,*}

¹Department of Emergency Medicine, Soonchunhyang University Bucheon Hospital, 14584 Bucheon, Republic of Korea

²Department of Emergency Medicine, InHa University Hospital, 22332 Incheon, Republic of Korea

***Correspondence**

brayden0819@daum.net
(Sangsoo Han)

† These authors contributed equally.

Abstract

Nausea and vomiting during pregnancy (NVP) occurs in up to 80% of pregnant women worldwide. Severe intractable NVP accompanied by acute starvation may threaten the health of the mother and fetus, and greatly reduce the quality of life during pregnancy. Symptoms that cannot be controlled with pharmacotherapy are difficult to relieve in severe NVP. Dysfunction of the autonomic and enteric nervous systems is an important component of NVP pathogenesis. It is thought to be controlled by the autonomic nervous system. In the present case, a 30-year-old married female came to the emergency department complaining of severe nausea and vomiting. Her symptoms had not improved with medication, such as Diclectin® and intravenous metoclopramide. Tenderness was detected in the multifidus area on both sides of the T7 spinal cord level. Normal saline (3 cc) was injected into the multifidus areas at both tenderness points, and her symptoms improved 30 min after the injections because intervertebral pressure and constriction of the vasa nervorum were alleviated. This approach improved the compression of sympathetic preganglionic fibers and increased blood flow to the sympathetic nerves. Nausea and vomiting symptoms improved as the imbalance in the autonomic nervous system improved and vagal tone was normalized. Sympathetic nerve entrapment point injection should be considered an alternative treatment to control severe NVP not resolved by medication.

Keywords

Morning sickness; Pregnancy; Autonomic nervous system; Sympathetic fibers

1. Introduction

Morning sickness refers to nausea and vomiting that occurs during pregnancy (NVP). It has an incidence of up to 80% worldwide [1]. NVP typically begins around week 9 of pregnancy and tends to peak at weeks 11–13. Most NVPs improve after 12–14 weeks but 1–10% of cases persist beyond 22 weeks [2]. Severe NVP that is refractory to treatment can increase the risk of abnormal fetal growth, miscarriage and preeclampsia [3]. Among types of NVP, hyperemesis gravidarum (HG) is defined as severe intractable NVP accompanied by acute starvation and includes weight loss, electrolyte abnormalities and ketonuria [4]. The prevalence of HG is 0.3–3%, and higher rates have been reported in Asian and Middle Eastern ethnicities [5]. HG can threaten the health of the mother and fetus, and greatly reduce the quality of life during pregnancy [6]. HG is also the most common cause of hospitalization during early pregnancy and the second most common cause of hospitalization during pregnancy after preterm birth [4, 7]. That is why it is important to control the symptoms of NVP. Pyridoxine and doxylamine are effective and safe first-line pharmacotherapies for relieving the symptoms of NVP [4].

Other drugs can be used for severe symptoms or HG that cannot be controlled with this pharmacotherapy but data on fetal safety are insufficient, so the risks and benefits should be considered before use [4].

Although the cause of NVP has not been identified, various factors are involved, such as hormonal changes and physical, immunological and psychological factors [7]. Dysfunction of the autonomic and enteric nervous systems is an important component of HG pathogenesis [2]. Thus, NVP is expected to be controlled by the autonomic nervous system.

In this paper, we introduce a case in which NVP was effectively controlled through sympathetic nerve entrapment point injection (SNEPI).

2. Case report

A 30-year-old married female came to the emergency department complaining of severe nausea and vomiting. The patient was primigravida in the ninth week of pregnancy, and she had developed symptoms 1 week previously. She was prescribed Diclectin® at a local clinic. Poor oral intake continued 3 days

before the visit, and she had lost about 2 kg compared to before the pregnancy.

She was a non-smoker and did not drink alcohol. She had no surgical, medical or gynecological history. A physical examination revealed a soft abdomen and no abdominal tenderness. The tongue was dry and ill-looking. She was alert, with no neck stiffness, no signs of meningeal irritation, and a normal neurological examination. Initial vital signs were blood pressure 110/60 mmHg; heart rate 110 beats per minute (bpm); and body temperature 36.9 °C. An electrocardiogram revealed sinus tachycardia.

In laboratory testing, the white blood cell count and electrolytes were in the normal reference range. Lactic acid was 2.8 mmol/L (reference range 0.5–2.0 mmol/L), and liver function and thyroid function tests were normal. Ketones and protein were negative in routine urinalysis. Abdominal ultrasonography was performed, and the abdominal cavity findings were normal. Transvaginal ultrasonography was performed in consultation with an obstetrician, and no specific findings were found for the uterus or fetus.

Intravenous (IV) infusion of 0.9% normal saline was administered for dehydration, and 10 mg IV metoclopramide was given to control symptoms. However, the patient's symptoms did not improve after 30 min, so she was re-examined. Tenderness was detected in the multifidus area on both sides of the T7 spinal cord. Before injection, the patient received sufficient information about the SNEPI and provided written informed consent for the therapeutic procedure. Normal saline (3 cc) was injected into the multifidus area on both sides (Fig. 1). The treatment effect was checked every 15 min. Mild nausea and vomiting remained 15 min after SNEPI. All of the symptoms improved after 30 min. The patient's vital signs were stable with a blood pressure of 118/83 mmHg and a heart rate of 95 bpm. She was discharged from the emergency room with no complaints of additional symptoms.

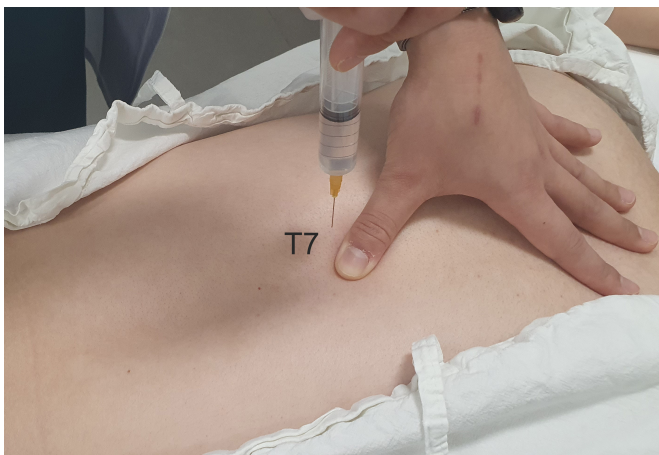


FIGURE 1. Sympathetic nerve entrapment point injection. Normal saline (3 cc) was injected into the multifidus area on both sides of the T7 spinal cord.

3. Discussion

Treatment for NVP is *via* diet and lifestyle control, and the first-line pharmacotherapy is pyridoxine and doxylamine [4]. However, symptoms can persist despite such attempts. In severe cases, HG occurs and seriously affects the health of the mother and fetus [5]. In this case, there were no findings about acute starvation such as electrolyte imbalance or ketonuria, so it was insufficient to diagnose HG. However, the management of severe refractory NVP is also important because it could affect the risk of abnormal fetal growth and miscarriage [3].

The nervous system may play a major role in the symptoms of NVP. The stomach is regulated by various nerves, such as motility, sphincter tone, acid-secreting, hormonal and blood flow [8]. The parasympathetic nerve action of the stomach occurs through the vagus nerve, which originates from the dorsal motor nucleus of the vagus in the brain stem, and plays a major role in regulating gastric acid secretion and smooth muscle contraction [9]. Sympathetic nerves that innervate the stomach arise at the T6–9 level and postganglionic sympathetic neurons use norepinephrine (NE) as the main neurotransmitter [9]. When a sympathetic nerve becomes excited, it inhibits gastrointestinal motility and induces vasoconstriction by acting on vascular smooth muscle to regulate gastric blood flow [9, 10]. Sympathetic preganglionic fibers are located in the intervertebral foramen of the corresponding level. When this point is overexcited by various stimuli, signals are excessively transmitted to the postganglionic fibers, which lead to excess secretion of NE from the terminal part of the nerve. This causes a decrease in the motility of the intestine and a temporary decrease in blood flow due to vasoconstriction [9, 11]. Consequently, this excess excitation of the sympathetic nerve leads to the failure of proper regulation, resulting in an imbalance in the autonomic nervous system, which causes nausea and vomiting [12, 13].

In this case, the patient had no specific findings in abdominal examinations, and there were no abnormal findings in laboratory tests or ultrasonography to differentiate other diseases. However, the patient complained of tenderness on both sides of the multifidus muscle at the T7 level. Symptoms improved by performing SNEPI in the T7 multifidus area. Nausea and vomiting seemingly occurred because the entrapped sympathetic nerve fibers were overstimulated at the corresponding level. Therefore, by performing SNEPI on the multifidus muscle, intervertebral pressure and constriction of the vasa nervorum were alleviated, which improved compression of the sympathetic preganglionic fibers and increased blood flow to the sympathetic nerve. Thus, the overexcited sympathetic nerves were normalized [11, 14]. As the imbalance in the autonomic nervous system improved and vagal tone was normalized, NVP symptoms improved *via* control of gastrointestinal motility and normalization of gastroesophageal junction pressure, gastric acid secretion and gastrointestinal blood flow.

There were several limitations to this study. First, this case report was that the patient was examined and treated at the emergency department, so it was not possible to confirm the recurrence of symptoms and further prognosis as there was no follow-up after discharge. Therefore, there was a limitation in accurately determining the effect of the SNEPI

treatment. Second, we couldn't compare the effect of other injection solutions such as lidocaine. We used only normal saline because the patient showed reluctance to the lidocaine. In previous studies about SNEPI, both normal saline and lidocaine showed efficacy [14, 15]. So, additional studies on an alternative SNEPI injection solution in pregnant women are needed. Third, we did not figure out the effect of SNEPI on HG patients. The mechanism of SNEPI that improves the imbalance in the autonomic nervous system and normalizes vagal tone could have a similar effect on the nausea and vomiting of HG patients. But patients' nutritional and metabolic conditions could affect the efficacy of SNEPI. So, a further study will be needed to determine whether SNEPI can effectively control symptoms in HG patients. Nevertheless, if other pathological diseases are excluded, SNEPI is an alternative treatment method for severe NVP symptoms that do not improve with medication. However, additional studies involving a larger number of patients are needed to demonstrate the therapeutic effect of SNEPI.

4. Conclusions

An imbalance in the autonomic nervous system affects the digestive capacity of the stomach, which can cause severe NVP. SNEPI is an alternative treatment to control severe NVP symptoms not resolved by medication.

AVAILABILITY OF DATA AND MATERIALS

Please contact author for data requests.

AUTHOR CONTRIBUTIONS

These should be presented as follows: SC, KK—designed the research study. SN, SK—performed the research. SH—provided help and advice on writing and design. SC, KK—wrote the manuscript. All authors contributed to editorial changes in the manuscript. All authors read and approved the final manuscript.

ETHICS APPROVAL AND CONSENT TO PARTICIPATE

The study protocol was approved by the Institutional Review Board of Soonchunhyang University Bucheon Hospital (IRB No. 2023-02-006). Participant provided written informed consent with guarantees of confidentiality.

ACKNOWLEDGMENT

Not applicable.

FUNDING

This work was supported by the Soonchunhyang University Research Fund (grant no. 2023-0022).

CONFLICT OF INTEREST

The authors declare no conflict of interest.

REFERENCES

- [1] Mares R, Morrow A, Shumway H, Zapata I, Forstein D, Brooks B. Assessment of management approaches for hyperemesis gravidarum and nausea and vomiting of pregnancy: a retrospective questionnaire analysis. *BMC Pregnancy and Childbirth*. 2022; 22: 609.
- [2] Hughes JD, Nayak NG, Aslam N, Rashed H, Cardoso S, Familoni B, *et al*. Autonomic and enteric nervous system dysfunction may play a role in hyperemesis gravidarum. *Gastroenterology Research*. 2015; 8: 153–156.
- [3] Herrell HE. Nausea and vomiting of pregnancy. *American Family Physician*. 2014; 89: 965–970.
- [4] Committee on Practice Bulletins-Obstetrics. ACOG practice bulletin No. 189: nausea and vomiting of pregnancy. *Obstetrics and Gynecology*. 2018; 131: e15–e30.
- [5] Syn NL, Chan S, Chia EWY, Ong WX, Phua D, Cai S, *et al*. Severity of nausea and vomiting in pregnancy and early childhood neurobehavioural outcomes: the growing up in Singapore towards healthy outcomes study. *Paediatric and Perinatal Epidemiology*. 2021; 35: 98–108.
- [6] Nana M, Tydeman F, Bevan G, Boulding H, Kavanagh K, Dean C, *et al*. Hyperemesis gravidarum is associated with increased rates of termination of pregnancy and suicidal ideation: results from a survey completed by >5000 participants. *American Journal of Obstetrics and Gynecology*. 2021; 224: 629–631.
- [7] Liu C, Zhao G, Qiao D, Wang L, He Y, Zhao M, *et al*. Emerging progress in nausea and vomiting of pregnancy and hyperemesis gravidarum: challenges and opportunities. *Frontiers in Medicine*. 2022; 10: 809270.
- [8] Liu W, Jin Y, Wilde PJ, Hou Y, Wang Y, Han J. Mechanisms, physiology, and recent research progress of gastric emptying. *Critical Reviews in Food Science and Nutrition*. 2021; 61: 2742–2755.
- [9] Browning KN, Travagli RA. Central nervous system control of gastrointestinal motility and secretion and modulation of gastrointestinal functions. *Comprehensive Physiology*. 2014; 4: 1339–1368.
- [10] Masliukov PM, Emanuilov AI, Budnik AF. Sympathetic innervation of the development, maturity, and aging of the gastrointestinal tract. To be published in *The Anatomical Record*. 2022. [Preprint].
- [11] Seong JW. Principle and insights into pain. 1st ed. Koonja Press: Seoul, South Korea. 2015.
- [12] Kornum DS, Terkelsen AJ, Bertoli D, Klinge MW, Høyer KL, Kufaiishi HHA, *et al*. Assessment of gastrointestinal autonomic dysfunction: present and future perspectives. *Journal of Clinical Medicine*. 2021; 10: 1392.
- [13] Kovacic K, Li BUK. Cyclic vomiting syndrome: a narrative review and guide to management. *Headache*. 2021; 61: 231–243.
- [14] Lee S, Oh CJ, Seong JW. Sympathetic nerve entrapment point injection as an antireflux procedure for refractory laryngopharyngeal reflux: a first case report of innovative autonomic regulation. *Innovations in Clinical Neuroscience*. 2016; 13: 32–36.
- [15] Nah S, Kim K, Choi S, Woo S, Han S. Sympathetic nerve entrapment point injection as an adjuvant treatment for intractable cluster headache: a case report. To be published in *The Journal of Emergency Medicine*. 2023. [Preprint].

How to cite this article: Sungwoo Choi, Kangho Kim, Sangun Nah, Sechan Kim, Sangsoo Han. Sympathetic nerve entrapment point injection for intractable nausea and vomiting in pregnancy: a case report. *Signa Vitae*. 2023. doi: 10.22514/sv.2023.122.