

ORIGINAL RESEARCH



Success of the emergency physician to recognize pathological diffusion-weighted magnetic resonance imaging in acute stroke patients

Mehmet Nuri Bozdemir^{1,*}, Mehmet Uynaz², Ahmet Celik², Bulent Cekic³, Mehmet Berk Eyinc¹, Mehmet Akcimen¹

¹Department of Emergency Medicine Antalya, Antalya Training and Research Hospital, University of Health Sciences, 07050 Antalya, Turkey

²Department of Emergency Medicine Urfa, Eyyubiye Training and Research Hospital, University of Health Sciences, 63050 Sanliurfa, Turkey

³Department of Radiology Antalya, Antalya Training and Research Hospital, University of Health Sciences, 07050 Antalya, Turkey

***Correspondence**

drnuribozdemir@yahoo.com.tr
(Mehmet Nuri Bozdemir)

Abstract

This study is aimed to evaluate the proficiency of emergency physicians in identifying ischemic strokes *via* diffusion-weighted magnetic resonance imaging (DW-MRI), and to determine the inter-rater agreement between emergency department (ED) residents and radiologists. The suspected ischemic stroke patients undergoing DW-MRI and not the candidates for thrombolytic therapy were eligible for the study. Diffusion MRI images were evaluated by the on-duty senior ED residents having two or more years in residency program, and a radiologist. Prior to the study, an instructor from radiology department delivered 2-hour theoretical and 2-hour practical lectures to ED physicians on the evaluation of diffusion MRI. A total of 604 patients were included in the study wherein 145 patients (24%) were detected with ischemic areas. The parietal lobe was the most prevalent ischemic area according to ED physicians' and radiologist's findings. ED residents and the radiologist had different interpretations for 54 patients. ED physicians ascribed 15 (3.4%) ischemic stroke patients as normal and 39 (23.1%) normal patients as stroke. ED physicians had 89.7% sensitivity (95% confidence interval (CI): 84% to 94%) and 91.5% specificity (95% CI: 89% to 94%) in diagnosing ischemic stroke. A good inter-rater agreement was found between ED physicians and the radiologist with kappa value of 0.77 (95% CI: 0.71 to 0.83). ED physicians have better success rate in interpreting DW-MRI to detect ischemic stroke in non-candidate cases of thrombolytic therapy (cases whose National Institutes of Health Stroke Scale (NIHSS) score is not appropriate, symptom onset exceeds 4.5 hours, and thrombolytic administration is contraindicated). There is a good inter-rater agreement between ED physicians and radiologist.

Keywords

Diffusion-weighted magnetic resonance imaging; Emergency medicine; Acute stroke

1. Introduction and purpose

Stroke has been the primary contributor of global mortality and morbidity. Ischemic stroke is 80% prevalent among all strokes. Fibrinolysis is the only therapeutic intervention to reverse neurological deficits of ischemic stroke. However, there is a confined time window for its application. The accurate and swift diagnosis, and identification of right patient is vital. Imaging modalities and neurological examinations have role in managing these patients [1].

Computerized tomography (CT) is the most used imaging tool in stroke patients to distinguish ischemic and hemorrhagic strokes because of its availability, however magnetic resonance imaging (MRI) is more advanced radiological method for detecting soft tissue pathologies with high resolution [2]. Furthermore, CT results in radiation exposure and has limitations of detecting lesions in posterior fossa, small lesions, and

stroke mimics [3].

Diffusion-weighted magnetic resonance imaging (DW-MRI) has distinct image contrast compared to conventional MRI techniques. DW-MRI is more sensitive than CT in detecting acute ischemic stroke. It can differentiate acute stroke from other conditions of sudden neurological deficits [4]. CT or DW-MRI interpretation is crucial because of the limited timeframe in these patients. The emergency department (ED) physicians are specialists in interpreting brain CT scans, however the same levels may not be possible for DW-MRI due to its recent introduction as diagnostic tool [5].

DW-MRI thus depends on the interpreter as in the case of other radiological tools. The lesion may be invisible, especially in the earlier moments of ischemia [6].

Artificial intelligence as a novel option of interpreting medical images is becoming common. However, its availability

is limited in most parts of the world. The physician-based evaluations of DW-MRI images will thus remain in practice.

This study is aimed to determine inter-rater agreement between ED residents and radiologists pertaining to the interpretation of DW-MRI images in ischemic stroke patients.

2. Materials and methods

2.1 Study design and setting

This cross-sectional study was conducted in the emergency department of tertiary care hospital from July 2017 to April 2018. The local ethics committee approved the study protocol.

2.2 Selection of study patients

Inclusion Criteria:

- Individuals ≥ 18 years age
- Underwent brain DW-MRI because of suspected ischemic stroke
- Patients with informed consent to participate

Exclusion Criteria:

- Individuals < 18 years age
- Patients with thrombolytic and thrombectomy decisions based on brain tomography (undergoing DW-MRI wasted time in those patients)
- Cases with appropriate NIH score, symptoms started in the last 4.5 hours, and thrombolytic administration indicated.
- Brain DW-MRI conducted due to trauma
- DW-MRI obtained outside the brain
- Non-consented patients

2.3 Selection of study participants

Seven senior ED residents having completed over two years of residency program were included in this segment of study participants. Participating assistants of the study blindly interpreted the images. The study forms were recorded with patients' demographic information, vital signs, their complaints, onset time and MRI findings.

The on-duty resident during MRI interpreted the MRI. MRI images were evaluated one after the other by emergency residents. The radiology segment of participants included on-duty radiologist along with a faculty member of Radiology Department serving as supervisor.

The present study was conducted with ED residents because of the insufficient number of attending ED physicians.

The participating ED residents of the study were trained by a radiologist *via* two-hour theoretical and two-hour practical DW-MRI training prior to the commencement of study.

2.4 DW-MRI interpretation

A brain DW-MRI image was recorded after recruiting eligible patients to the study. Actively participating ED resident of the study interpreted the images. An on-duty radiology ED resident independently interpreted the DW-MRI images. However, a faculty member from Radiology Department with 15 years of experience inspected the images in final analysis. His findings were accepted as the gold standard since he had interest and expertise in MRI.

2.5 Magnetic resonance imaging

Brain DW-MRI for the study subjects were acquired using Siemens (1.5 tesla) and Philips (1.5 tesla) MR devices. Images were assessed by the pre-installed Sectra brand PACS system on hospital computers.

2.6 Statistical analysis

The data were analyzed by Statistical Package for the Social Sciences (SPSS) 21 statistical software package (IBM Corporation, Chicago, IL, USA) and MedCalc (MedCalc Software Ltd. Ostend, Belgium) ver. 20.110. Numeric data were presented as mean \pm standard deviation while categorical data as rates. The Chi-square test compared the rates among three or more groups having categorical data.

Inter-rater agreement between ED residents and radiologists was determined through the kappa value. This agreement was defined as excellent with kappa value > 0.80 , good between $0.61-0.80$, moderate between $0.41-0.60$, fair between $0.21-0.40$, and poor if < 0.20 .

Sensitivity, specificity, and area under the curve (AUC) were employed to detect ischemic stroke in DW-MRI by the ED physicians. The point estimates were computed at 95% confidence interval.

The hypotheses were formulated as two-tailed, and alpha critical value of 0.05 was considered significant.

3. Results

A total of 604 patients were included in the study wherein 331 (55%) were male and 273 (45%) female. Patients had the mean age of 63 ± 12 years.

ED physicians could accurately determine the localization compared to radiologists. The parietal lobe was the most prevalent ischemic area according to ED physicians' and radiologists' findings (Table 1).

DW-MRI analysis revealed 145 (24%) patients detected with ischemic area. ED physicians had 89.7% sensitivity (95% CI: 84% to 94%) and 91.5% specificity (95% CI: 89% to 94%) in diagnosing ischemic stroke (Table 2). AUC value was 0.91 (95% CI: 0.88 to 0.93) for the ED residents in interpreting DW-MRI for ischemic stroke (Fig. 1).

ED residents and the radiologist interpreted differently for 54 patients. ED physicians designated 15 (3.4%) ischemic stroke patients as normal, and 39 (23.1%) normal patients as stroke (Table 2).

A good inter-rater agreement was found between ED physicians and the radiologist with kappa value of 0.77 (95% CI: 0.71 to 0.83).

No difference was observed between ED residents regarding the accuracy of establishing ischemic stroke *via* DW-MRI ($p = 0.967$) (Table 3).

4. Discussion

This study depicted good inter-rater agreement of ED residents and a radiologist in detecting ischemic stroke from DW-MRI of non-candidate patients for thrombolytic therapy.

MRI imaging required experienced MRI technician, trained

TABLE 1. Locations of ischemic strokes assigned by ED physician and radiologist in DWI-MRI.

Localization of Ischemic Stroke	Emergency Physicians	Radiology Physician
Cerebellum	18 (3.0%)	8 (1.3%)
Bulbus	5 (0.8%)	2 (0.3%)
Pons	11 (1.8%)	10 (1.7%)
Mesencephalon	12 (2.0%)	7 (1.2%)
Parietal Lobe	62 (10.3%)	67 (11.1%)
Frontal Lobe	4 (0.7%)	14 (2.3%)
Temporal Lobe	19 (3.1%)	21 (3.5%)
Occipital Lobe	19 (3.1%)	15 (2.5%)
Putamen	21 (3.5%)	9 (1.5%)
Lentiform nucleus	18 (3.0%)	9 (1.5%)
Nucleus caudatus	20 (3.3%)	13 (2.2%)
Insula	3 (0.5%)	8 (1.3%)
Middle Cerebral Artery	22 (3.6%)	15 (2.5%)
Posterior Cerebral Artery	4 (0.7%)	6 (1.0%)
Anterior Cerebral Artery	5 (0.8%)	1 (0.2%)

All the variables are expressed as frequency (*n*) and percentage.

TABLE 2. 2 × 2 table depicting the consistency of ED physicians and radiologists in interpreting DWI for ischemic stroke.

	Radiologist		Total
	Ischemia (-)	Ischemia (+)	
Emergency Physicians			
Ischemia (-)	420 (96.6%)	15 (3.4%)	435 (72.0%)
Ischemia (+)	39 (23.1%)	130 (76.9%)	169 (28.0%)
Total	459 (76.0%)	145 (24.0%)	604 (100.0%)

radiologist to interpret the data, and patient compatibility [7]. The radiologists might misinterpret MRI images in ED because of time constraint. A study reported the concordance of 84.8% upon comparing the DW-MRI interpretations of radiology residents in ED and the neuroradiologists [8]. A study revealed that the rate of misdiagnosis for ischemic stroke by ED physicians was 5% to 33% [9]. In a similar study, 14% ischemic stroke-related findings in DW-MRI were missed by ED physicians [10].

The overall false negative (3.4%) and false positive (23.1%) rates by ED residents in the present study were 26.5%. The rate of missing an ischemic stroke patient was low, whereas assigning a normal patient as ischemic stroke was more probable. This would increase the unnecessary patients' admissions. On the contrary, missing an ischemic stroke was in acceptable limits, however the improper discharge be avoided based on their clinical manifestations.

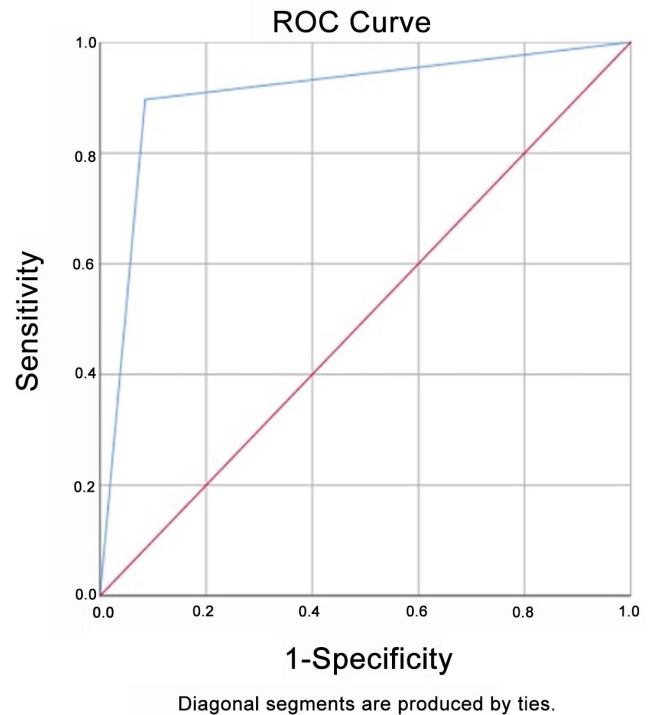


FIGURE 1. ROC curve displaying the success rate of ED physicians in interpreting DW-MRI for acute ischemic stroke. ROC: receiver operating characteristic.

TABLE 3. Success of emergency physicians in detecting ischemic stroke in DW-MRI.

Physician	Correct Interpretation	Incorrect Interpretation
1. Physician	106 (90.6%)	11 (9.4%)
2. Physician	81 (92.0%)	7 (8.0%)
3. Physician	95 (93.1%)	7 (6.9%)
4. Physician	86 (90.5%)	9 (9.5%)
5. Physician	60 (88.2%)	8 (11.8%)
6. Physician	59 (90.7%)	6 (9.3%)
7. Physician	63 (91.3%)	6 (8.7%)
Total	550 (91.0%)	54 (9.0%)
Total	604 patients	
<i>p</i> Value	0.967	

The radiological instruments had been user dependent. A perfect inter-rater agreement was barely possible among the radiologists, and between the radiologists and other specialists. The inter-rater agreement between ED physicians and radiologists would improve by practicing and interpreting MRI in ED. So, a study on the success of experienced ED physicians would be of interest in future investigations.

In our country, stroke centers and stroke teams had been established for treating ischemic stroke. Minutes were important in starting the stroke treatment, as it was the main cause of mortality and morbidity in our country. The frontline emergency physicians could have role in managing these patients *via* the rapid ischemic stroke detection. The rapid detection relied on

clinical manifestations, and accurate interpretation of radiological outcomes. CT scans had been the ubiquitous imaging tools in EDs, however, DW-MRI had become common for ED patients as compared to the past. ED physicians should thus interpret the DW-MRI scans of potential ischemic stroke patients who were not eligible for thrombolytics. Patients in the thrombolytics period would also be of interest for future studies.

5. Limitations

This study had several limitations. Patients in the thrombolytic period were not included. Different periods for symptom onset could impact the interpretations of either group. The study did not involve residents with less than two years of experience and preferring more experienced physicians than the senior residents. Including these segments in the study might have influenced the findings.

A two-hour training session might not be sufficient for conducive DW-MRI interpretations. The present study should thus be replicated by more experienced and trained ED physicians to interpret DW-MRI.

6. Conclusions

ED physicians have high success rate of interpreting DW-MRI ischemic strokes in non-candidate cases of thrombolytic therapy (cases with inappropriate NIH score, symptom onset exceeds 4.5 hours, and thrombolytic administration is contraindicated). There is a good inter-rater agreement between ED physicians and radiologist. Providing training and practice to ED physicians in DW-MRI interpretation of acute ischemic stroke can enhance their success rates.

AVAILABILITY OF DATA AND MATERIALS

We used Antalya Education and Research Hospital's data system and sources (PACS System of CT scan, MRI).

AUTHOR CONTRIBUTIONS

MNB—designed the research study. MU, AC—performed the research. BC, MBE—wrote the manuscript. MA—analyzed the data. All authors read and approved the final manuscript.

ETHICS APPROVAL AND CONSENT TO PARTICIPATE

We had permission from Antalya Education and Research Hospital's Ethical Committee which is dated 23 June 2017 and numbered 11/05. We have not used any kind of harmful intervention, drug, etc. We just screened all of the patients who enrolled this study, gathered information of all. This study is compatible with Human Right's Laws. After we had permission of ethical approval, we have gotten signed permission from each patient and their relatives.

ACKNOWLEDGMENT

Not applicable.

FUNDING

This research received no external funding.

CONFLICT OF INTEREST

The authors declare no conflict of interest.

REFERENCES

- [1] Mendelson SJ, Prabhakaran S. Diagnosis and management of transient ischemic attack and acute ischemic stroke. *JAMA*. 2021; 325: 1088.
- [2] Wu C, Ferreira F, Fox M, Harel N, Hattangadi-Gluth J, Horn A, *et al*. Clinical applications of magnetic resonance imaging based functional and structural connectivity. *NeuroImage*. 2021; 244: 118649.
- [3] Shinohara Y, Ohmura T, Ibaraki M, Itoh T, Sasaki F, Sato Y, *et al*. Non-contrast dual-energy CT using X-map for acute ischemic stroke: region-specific comparison with simulated 120-kVp CT and diffusion-weighted MR images. *Japanese Journal of Radiology*. 2024; 42: 165–173.
- [4] Powers WJ, Rabinstein AA, Ackerson T, Adeoye OM, Bambakidis NC, Becker K, *et al*. Guidelines for the early management of patients with acute ischemic stroke: 2019 update to the 2018 guidelines for the early management of acute ischemic stroke: a guideline for healthcare professionals from the American heart association/American stroke association. *Stroke*. 2019; 50: e344–e418.
- [5] Onder H, Guncu O, Hasgul B, Dayangac I, Gungorer B. The reliability of the evaluation of diffusion-weighted imaging in suspected stroke by emergency physicians. *Journal of Neurosciences in Rural Practice*. 2020; 11: 151–155.
- [6] Magyar M, Tóth A, Nyilas NL, Biró I, Rudas G, Maurovich Horvat P, *et al*. The importance of MR imaging in the diagnosis and management of acute stroke. *Ideggyógyászati Szemle*. 2023; 76: 233–244. (In Hungarian)
- [7] Nagaraja N. Diffusion weighted imaging in acute ischemic stroke: a review of its interpretation pitfalls and advanced diffusion imaging application. *Journal of the Neurological Sciences*. 2021; 425: 117435.
- [8] Lee S, Baek HJ, Jung HK, Moon JI, Cho SB, Choi BH, *et al*. Interpretations of diffusion-weighted MR imaging by radiology residents in the emergency department: is diagnostic performance influenced by the level of residency training? *La Radiologia Medica*. 2017; 122: 35–42.
- [9] Oray D, Limon O, Ertan C, Aydinoglu Ugurhan A, Sahin E. Inter-observer agreement on diffusion-weighted magnetic resonance imaging interpretation for diagnosis of acute ischemic stroke among emergency physicians. *Turkish Journal of Emergency Medicine*. 2015; 15: 64–68.
- [10] Madsen TE, Khoury J, Cadena R, Adeoye O, Alwell KA, Moomaw CJ, *et al*. Potentially missed diagnosis of ischemic stroke in the emergency department in the greater Cincinnati/Northern Kentucky stroke study. *Academic Emergency Medicine*. 2016; 23: 1128–1135.

How to cite this article: Mehmet Nuri Bozdemir, Mehmet Uynaz, Ahmet Celik, Bulent Cekic, Mehmet Beerck Eyinc, Mehmet Akcimen. Success of the emergency physician to recognize pathological diffusion-weighted magnetic resonance imaging in acute stroke patients. *Signa Vitae*. 2024; 20(6): 74-77. doi: 10.22514/sv.2024.048.